A 62-year-old man comes to the office due to decreased libido and failure to achieve satisfactory erections. Medical history is notable for coronary artery disease, hypertension, atrial fibrillation, and heart failure with reduced ejection fraction, for which he takes a number of medications. Blood pressure is 110/70 mm Hg and pulse is 70/min. Oxygen saturation on room air is 95%. Examination shows a left ventricular third heart sound and trace pitting ankle edema. Breast examination reveals bilateral breast enlargement with mild tenderness. Which of the following is the most likely cause of this patient's current symptoms?

- A. ACE inhibitor
- B. Antiplatelet agent
- C. Beta-blocker
- D. Direct oral anticoagulant
- E. Loop diuretic
- F. Neprilysin inhibitor
- G. Potassium-sparing diuretic

Submit

A 62-year-old man comes to the office due to decreased libido and failure to achieve satisfactory erections. Medical history is notable for coronary artery disease, hypertension, atrial fibrillation, and heart failure with reduced ejection fraction, for which he takes a number of medications. Blood pressure is 110/70 mm Hg and pulse is 70/min. Oxygen saturation on room air is 95%. Examination shows a left ventricular third heart sound and trace pitting ankle edema. Breast examination reveals bilateral breast enlargement with mild tenderness. Which of the following is the most likely cause of this patient's current symptoms?

- A. ACE inhibitor (1%)
- B. Antiplatelet agent (0%)
- C. Beta-blocker (7%)
- D. Direct oral anticoagulant (0%)
- E. Loop diuretic (1%)
- F. Neprilysin inhibitor (1%)
- ✓ G. Potassium-sparing diuretic (87%)

Omitted
Correct answer
G

87%
Answered correctly

28 secs
Time Spent

05/06/2020
Last Updated

Explanation

Medication-induced gynecomastia*	

Medication-induced gynecomastia*	
Drug	**Mechanism**
Estrogens	Direct stimulation of ductal epithelial hyperplasia
Antiandrogens (eg, flutamide, bicalutamide)	Competitive inhibition of testosterone receptor
5-alpha reductase inhibitors (eg, finasteride)	↓ Conversion of testosterone to dihydrotestosterone
Spironolactone	↓ Testosterone synthesis & inhibition of testosterone receptor
Ketoconazole	↓ Synthesis of steroid hormones (↓ androgen > ↓ estrogen)
Cimetidine	Inhibition of testosterone receptor
Androgen-anabolic steroids	Aromatization of androgens to estrogen

*Drugs that increase the estrogen-to-testosterone ratio are associated with gynecomastia.

This patient is most likely being treated with **spironolactone**, an aldosterone antagonist that acts as a **potassium-sparing diuretic**. In patients with **heart failure**, it reduces retention of sodium and water and attenuates the pathologic cardiac remodeling and deterioration in left ventricular function caused by local effects of aldosterone.

However, spironolactone also has prominent antiandrogenic effects due to **blockade of the androgen receptor** and **decreased testosterone** production. **Gynecomastia** is abnormal growth of male breast tissue caused by a decrease in the physiologic androgen-to-estrogen ratio and is a common adverse effect of spironolactone. Other antiandrogenic symptoms may include decreased libido and impotence. Eplerenone, a more selective aldosterone antagonist, has fewer endocrine adverse effects and can be used in place of spironolactone.

(Choices A and F) Neprilysin inhibitors (eg, sacubitril) decrease the breakdown of atrial natriuretic peptide and brain natriuretic peptide, facilitating the effects of these hormones on vasodilation and diuresis. Adverse effects include angioedema because sacubitril also inhibits bradykinin. ACE inhibitors have a similar adverse effect profile but neither of these drug classes affects testosterone metabolism or causes

function caused by local effects of aldosterone.

However, spironolactone also has prominent antiandrogenic effects due to **blockade of the androgen receptor** and **decreased testosterone** production. **Gynecomastia** is abnormal growth of male breast tissue caused by a decrease in the physiologic androgen-to-estrogen ratio and is a common adverse effect of spironolactone. Other antiandrogenic symptoms may include decreased libido and impotence. Eplerenone, a more selective aldosterone antagonist, has fewer endocrine adverse effects and can be used in place of spironolactone.

(Choices A and F) Neprilysin inhibitors (eg, sacubitril) decrease the breakdown of atrial natriuretic peptide and brain natriuretic peptide, facilitating the effects of these hormones on vasodilation and diuresis. Adverse effects include angioedema because sacubitril also inhibits bradykinin. ACE inhibitors have a similar adverse effect profile but neither of these drug classes affects testosterone metabolism or causes gynecomastia.

(Choices B and D) Antiplatelet agents (eg, aspirin, clopidogrel) and direct oral anticoagulants (eg, apixaban, dabigatran) can cause epistaxis and gastrointestinal bleeding but do not affect androgen metabolism.

(Choice C) Common adverse effects of beta-blockers (eg, carvedilol) include fatigue, hypotension, and bradycardia. They may have a small effect on erectile function but do not affect sex hormone levels or cause gynecomastia.

(Choice E) Loop diuretics (eg, furosemide) reduce edema in patients with heart failure. They can cause hypovolemia, hypotension, and electrolyte abnormalities but do not have a significant antiandrogenic effect.

Educational objective:
Spironolactone is an aldosterone antagonist commonly used to treat heart failure. It has significant antiandrogenic effects and can cause gynecomastia, decreased libido, and impotence. Eplerenone is a more selective aldosterone antagonist with fewer adverse effects.

References

- Safety profile of mineralocorticoid receptor antagonists: spironolactone and eplerenone.

Pharmacology	Male Reproductive System	Gynecomastia
Subject	System	Topic

Copyright © UWorld. All rights reserved.

function caused by local effects of aldosterone.

Exhibit Display

Effects of the natriuretic peptides

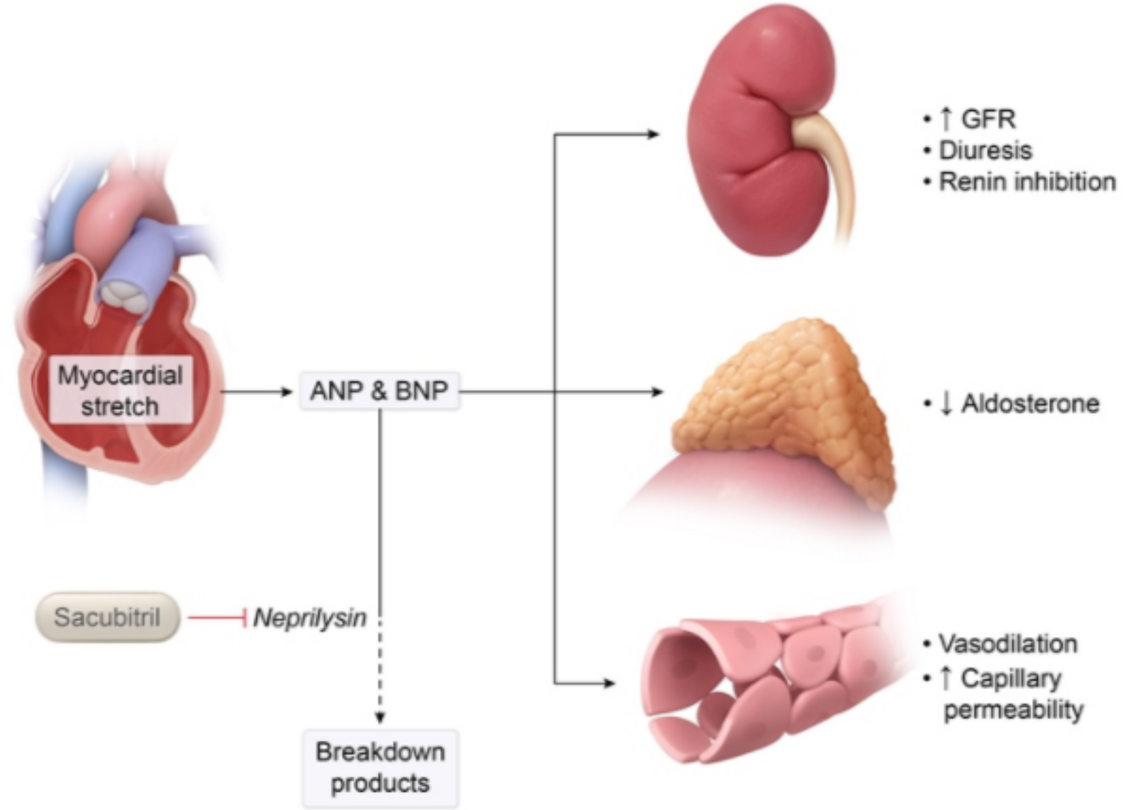

ANP = atrial natriuretic peptide; **BNP** = brain natriuretic peptide; **GFR** = glomerular filtration rate.

©UWorld

Zoom In | Zoom Out | Reset | Add To New Card | Existing Card

A 64-year-old man comes to the office due to urinary frequency, hesitancy, and dribbling. His symptoms began insidiously 5 years ago and have progressively worsened. He has to get up 2 or 3 times each night to urinate. Vital signs are normal. Examination shows a smooth, symmetrically enlarged prostate without nodules or tenderness. There is no suprapubic tenderness. Prostate-specific antigen level is 3.5 ng/mL, creatinine is 1.2 mg/dL, and urinalysis is normal. The patient is started on a new medication. After 6 months of therapy, his urinary symptoms improve and prostate volume decreases by 20%. Which of the following medications is most likely responsible for the decreased prostate volume in this patient?

A. Finasteride
B. Phenazopyridine
C. Tadalafil
D. Tamsulosin
E. Tolterodine

Submit

A 64-year-old man comes to the office due to urinary frequency, hesitancy, and dribbling. His symptoms began insidiously 5 years ago and have progressively worsened. He has to get up 2 or 3 times each night to urinate. Vital signs are normal. Examination shows a smooth, symmetrically enlarged prostate without nodules or tenderness. There is no suprapubic tenderness. Prostate-specific antigen level is 3.5 ng/mL, creatinine is 1.2 mg/dL, and urinalysis is normal. The patient is started on a new medication. After 6 months of therapy, his urinary symptoms improve and prostate volume decreases by 20%. Which of the following medications is most likely responsible for the decreased prostate volume in this patient?

- ✓ A. Finasteride (82%)
- B. Phenazopyridine (0%)
- C. Tadalafil (1%)
- D. Tamsulosin (14%)
- E. Tolterodine (0%)

Omitted
Correct answer
A

82%
Answered correctly

02 secs
Time Spent

06/01/2020
Last Updated

Explanation

Medical therapy for benign prostatic hyperplasia	
Alpha-adrenergic antagonists (eg, terazosin, tamsulosin)	• Relax smooth muscle in bladder neck, prostate capsule & prostatic urethra • Usual first-line therapy

Medical therapy for benign prostatic hyperplasia	
Alpha-adrenergic antagonists (eg, terazosin, tamsulosin)	• Relax smooth muscle in bladder neck, prostate capsule & prostatic urethra • Usual first-line therapy • **Side effects**: orthostatic hypotension, dizziness
5-alpha-reductase inhibitors (eg, finasteride, dutasteride)	• Inhibit conversion of testosterone to dihydrotestosterone • Reduce prostate gland size • Effectiveness may take 6-12 months • **Side effects**: decreased libido, erectile dysfunction
Antimuscarinics (eg, tolterodine)	• Used to treat overactive bladder (urinary frequency, urgency & incontinence) • **Side effects**: urine retention, dry mouth

This patient has **benign prostatic hyperplasia** (BPH). BPH is due to the effects of dihydrotestosterone on prostatic epithelial cells and is characterized by progressive prostatic enlargement with age, leading to **bladder outlet obstruction** and incomplete bladder emptying. Typical symptoms include urinary frequency, nocturia, hesitancy, and weak urinary stream. The bladder outlet obstruction is made up of a **dynamic component** (smooth muscle tone in the bladder neck, prostate capsule, and prostatic urethra) and a **fixed component** (structural effects of the enlarged prostate).

Alpha adrenergic antagonists (eg, terazosin, tamsulosin) are smooth muscle relaxants that work on the dynamic component of bladder outlet obstruction. They work within days to weeks. However, these drugs do not significantly affect prostate volume **(Choice D)**. **5-alpha reductase inhibitors** (eg, finasteride, dutasteride) inhibit the conversion of testosterone to dihydrotestosterone and address the fixed component of bladder outlet obstruction. Over time, they reduce prostate volume but can take up to 6-12 months to achieve maximal effect.

(Choice B) Phenazopyridine is a urinary analgesic that provides symptomatic relief of dysuria in urinary tract infections. It is not effective for BPH and does not affect prostate volume.

(Choice C) Tadalafil is a phosphodiesterase-5 inhibitor that is primarily used to treat erectile dysfunction. Although some studies have shown symptom improvement in BPH, tadalafil does not significantly decrease prostate volume.

characterized by progressive prostatic enlargement with age, leading to **bladder outlet obstruction** and incomplete bladder emptying. Typical symptoms include urinary frequency, nocturia, hesitancy, and weak urinary stream. The bladder outlet obstruction is made up of a **dynamic component** (smooth muscle tone in the bladder neck, prostate capsule, and prostatic urethra) and a **fixed component** (structural effects of the enlarged prostate).

Alpha adrenergic antagonists (eg, terazosin, tamsulosin) are smooth muscle relaxants that work on the dynamic component of bladder outlet obstruction. They work within days to weeks. However, these drugs do not significantly affect prostate volume **(Choice D)**. **5-alpha reductase inhibitors** (eg, finasteride, dutasteride) inhibit the conversion of testosterone to dihydrotestosterone and address the fixed component of bladder outlet obstruction. Over time, they reduce prostate volume but can take up to 6-12 months to achieve maximal effect.

(Choice B) Phenazopyridine is a urinary analgesic that provides symptomatic relief of dysuria in urinary tract infections. It is not effective for BPH and does not affect prostate volume.

(Choice C) Tadalafil is a phosphodiesterase-5 inhibitor that is primarily used to treat erectile dysfunction. Although some studies have shown symptom improvement in BPH, tadalafil does not significantly decrease prostate volume.

(Choice E) Antimuscarinics (eg, tolterodine) are used to treat overactive bladder symptoms (eg, urinary frequency, urgency, incontinence). They can cause urine retention and are normally used in BPH only once another drug has addressed the bladder outlet obstruction. They do not affect prostate volume.

Educational objective:
5-alpha reductase inhibitors (eg, finasteride, dutasteride) block the conversion of testosterone to dihydrotestosterone in the prostate. These drugs reduce prostate volume in patients with benign prostatic hyperplasia and relieve the fixed component of bladder outlet obstruction.

References

- Finasteride for benign prostatic hyperplasia.

Pharmacology	Male Reproductive System	Benign prostatic hyperplasia
Subject	System	Topic

Copyright © UWorld. All rights reserved.

An 18-year-old woman comes to the office for evaluation of acne. The patient is very upset about the acne scarring, which worsened since she started college. She has been very stressed by upcoming examinations and feels "exhausted" due to lack of adequate sleep. The patient has been using topical benzoyl peroxide and tretinoin for the past year. She was also prescribed an oral antibiotic but stopped taking it several months ago due to lack of improvement. The patient is sexually active with her boyfriend and uses an intrauterine device for contraception. Her periods are regular and last 5 days. She takes no other medications and does not use tobacco, alcohol, or illicit drugs. Physical examination shows nodulocystic acne with scarring on the face, chin, and upper back. The patient is interested in isotretinoin treatment. Which of the following is the best next step in management of this patient?

A. Bone density test
B. Pelvic ultrasound
C. Removal of intrauterine device
D. Serum retinol level
E. Serum testosterone
F. Serum TSH level
G. Urine β-hCG

Submit

Exhibit Display

Zoom In
Zoom Out
Reset
Add To New Card | Existing Card

An 18-year-old woman comes to the office for evaluation of acne. The patient is very upset about the acne scarring, which worsened since she started college. She has been very stressed by upcoming examinations and feels "exhausted" due to lack of adequate sleep. The patient has been using topical benzoyl peroxide and tretinoin for the past year. She was also prescribed an oral antibiotic but stopped taking it several months ago due to lack of improvement. The patient is sexually active with her boyfriend and uses an intrauterine device for contraception. Her periods are regular and last 5 days. She takes no other medications and does not use tobacco, alcohol, or illicit drugs. Physical examination shows nodulocystic acne with scarring on the face, chin, and upper back. The patient is interested in isotretinoin treatment. Which of the following is the best next step in management of this patient?

- A. Bone density test (0%)
- B. Pelvic ultrasound (2%)
- C. Removal of intrauterine device (2%)
- D. Serum retinol level (4%)
- E. Serum testosterone (4%)
- F. Serum TSH level (1%)
- ✓ G. Urine β-hCG (84%)

Omitted
Correct answer
G

84%
Answered correctly

09 secs
Time Spent

03/08/2020
Last Updated

Explanation

Side effects of oral isotretinoin therapy

- Teratogenic (eg, spontaneous abortion, fetal malformations)
- Hyperlipidemia
- Chelitis, dry skin
- Myalgias
- Pseudotumor cerebri

©UWorld

Isotretinoin is a synthetic 13-*cis*-isomer of naturally occurring all-*trans*-retinoic acid (tretinoin), a derivative of vitamin A. It can be administered orally to treat severe acne associated with significant **scarring**. It is also indicated in patients who fail therapy with topical tretinoin/benzoyl peroxide and antibiotics. Retinoids inhibit follicular epidermal keratinization, thereby loosening the keratin plugs of comedones and facilitating their expulsion. They also reduce the size of sebaceous glands and inhibit sebum production.

Isotretinoin is a potent teratogen and is absolutely **contraindicated in pregnancy**. Exposure to this medication can cause spontaneous abortion and a variety of severe fetal anomalies. A **negative pregnancy test** (urine or serum) is required prior to prescribing, and abstinence/contraception is recommended. Monthly pregnancy testing is required during treatment. An intrauterine device (IUD) is a long-term contraception method that is 99% effective and safe to use in women of all ages. It should not be discontinued in this patient **(Choice C)**. Because no contraception method is 100% effective, condom use as a backup method is advised.

(Choice A) Bone density testing is recommended in patients on long-term glucocorticoid therapy because these drugs increase bone resorption and reduce bone formation. Skeletal complications from isotretinoin therapy are rare.

(Choices B and E) Pelvic ultrasound and serum testosterone are used to diagnose polycystic ovary syndrome (PCOS), a major underlying cause of acne. PCOS commonly presents with oligomenorrhea and hirsutism, which are absent in this patient. Pelvic ultrasound often reveals ovaries with multiple small cysts. Treatment with oral contraceptives restores menses and alleviates acne.

©UWorld

Isotretinoin is a synthetic 13-*cis*-isomer of naturally occurring all-*trans*-retinoic acid (tretinoin), a derivative of vitamin A. It can be administered orally to treat severe acne associated with significant **scarring**. It is also indicated in patients who fail therapy with topical tretinoin/benzoyl peroxide and antibiotics. Retinoids inhibit follicular epidermal keratinization, thereby loosening the keratin plugs of comedones and facilitating their expulsion. They also reduce the size of sebaceous glands and inhibit sebum production.

Isotretinoin is a potent teratogen and is absolutely **contraindicated in pregnancy**. Exposure to this medication can cause spontaneous abortion and a variety of severe fetal anomalies. A **negative pregnancy test** (urine or serum) is required prior to prescribing, and abstinence/contraception is recommended. Monthly pregnancy testing is required during treatment. An intrauterine device (IUD) is a long-term contraception method that is 99% effective and safe to use in women of all ages. It should not be discontinued in this patient **(Choice C)**. Because no contraception method is 100% effective, condom use as a backup method is advised.

(Choice A) Bone density testing is recommended in patients on long-term glucocorticoid therapy because these drugs increase bone resorption and reduce bone formation. Skeletal complications from isotretinoin therapy are rare.

(Choices B and E) Pelvic ultrasound and serum testosterone are used to diagnose polycystic ovary syndrome (PCOS), a major underlying cause of acne. PCOS commonly presents with oligomenorrhea and hirsutism, which are absent in this patient. Pelvic ultrasound often reveals ovaries with multiple small cysts. Treatment with oral contraceptives restores menses and alleviates acne.

(Choice D) Vitamin A deficiency is rare in developed countries. Unlike vitamin A, isotretinoin is not stored in the liver and is therefore not associated with toxicities seen with high-dose vitamin A intake. Serum retinol measurement is not indicated.

(Choice F) Hypothyroidism commonly causes fatigue in addition to cold intolerance and constipation, but it does not cause acne. In addition, serum TSH would be elevated in a patient with hypothyroidism.

Educational objective:
Isotretinoin is used to treat severe acne with significant scarring. Pregnancy is an absolute contraindication due to the risk of teratogenicity. Sexually active women should be advised to use 2 forms of contraception and take monthly pregnancy tests.

References

- Possible long-term teratogenic effect of isotretinoin in pregnancy.

Isotretinoin is a synthetic 13-*cis*-isomer of naturally occurring all-*trans*-retinoic acid (tretinoin), a derivative of vitamin A. It can be administered

Exhibit Display

Retinoid mechanism of action

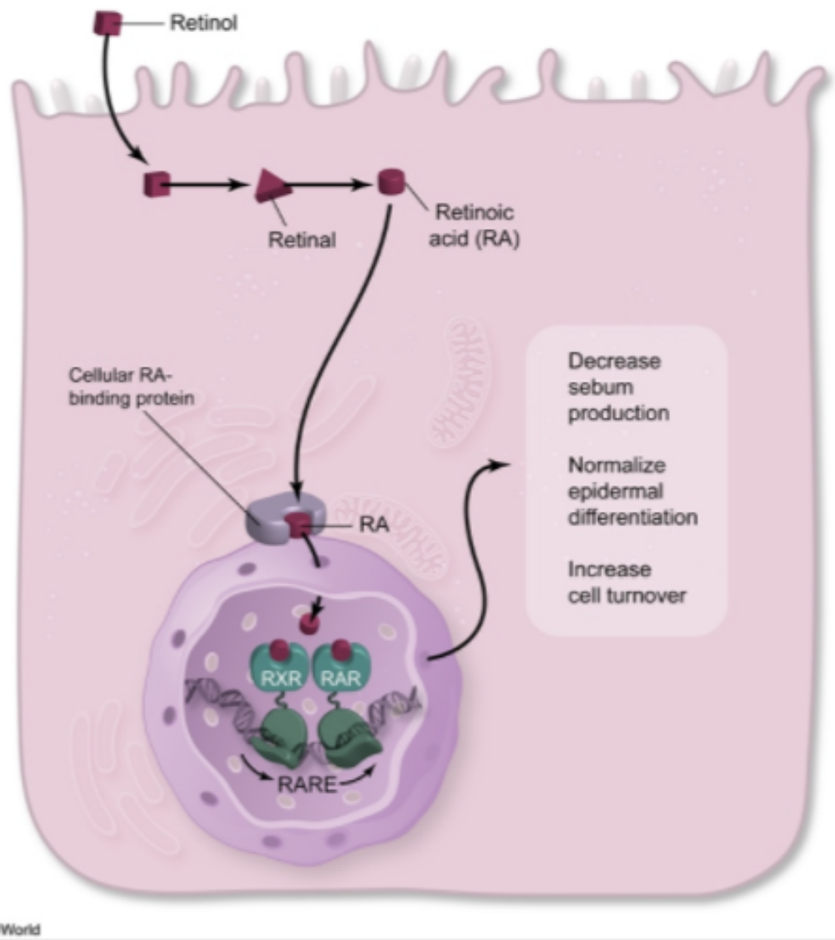

Zoom In | Zoom Out | Reset | Add To New Card | Existing Card

A 65-year-old man with benign prostatic hyperplasia has moderately severe symptoms and is started on finasteride. After six months of treatment with finasteride, his symptoms improve markedly and his prostate has regressed in size. Which of the following histological patterns was most likely present at the time of initiation of treatment?

A. Hyperplasia of prostate with predominance of epithelial components

B. Hyperplasia of prostate with predominance of muscular element

C. Hyperplasia of prostate with predominance of collagen

D. Hyperplasia of prostate with predominance of both collagen and smooth muscles

Submit

A 65-year-old man with benign prostatic hyperplasia has moderately severe symptoms and is started on finasteride. After six months of treatment with finasteride, his symptoms improve markedly and his prostate has regressed in size. Which of the following histological patterns was most likely present at the time of initiation of treatment?

- ✓ A. Hyperplasia of prostate with predominance of epithelial components (38%)
- B. Hyperplasia of prostate with predominance of muscular element (28%)
- C. Hyperplasia of prostate with predominance of collagen (4%)
- D. Hyperplasia of prostate with predominance of both collagen and smooth muscles (28%)

Omitted
Correct answer
A

38%
Answered correctly

02 secs
Time Spent

03/24/2020
Last Updated

Explanation

Finasteride is a **5-alpha reductase inhibitor** and it inhibits the conversion of testosterone to dihydrotestosterone. It acts on the **epithelial** components of the prostate gland and produces improvement of symptoms as well as reduction in the size of the gland. There are various histological patterns of BPH. Some patients have predominant epithelial hyperplasia and others have predominant stromal hyperplasia. Those with stromal hyperplasia may have collagen or smooth muscle predominance. Patients with epithelial predominance best respond to treatment with finasteride.

(Choice B, C & D) Alpha-1 blockers produce symptomatic improvement in patients with BPH by their action on smooth muscles present in prostate and bladder base. Patients with smooth muscle predominance best respond to treatment with alpha-1 blockers. Patients with collagen predominance respond neither to finasteride nor to alpha-1 blockers.

C. Hyperplasia of prostate with predominance of collagen (4%)

D. Hyperplasia of prostate with predominance of both collagen and smooth muscles (28%)

Omitted
Correct answer
A

38%
Answered correctly

02 secs
Time Spent

03/24/2020
Last Updated

Explanation

Finasteride is a **5-alpha reductase inhibitor** and it inhibits the conversion of testosterone to dihydrotestosterone. It acts on the **epithelial** components of the prostate gland and produces improvement of symptoms as well as reduction in the size of the gland. There are various histological patterns of BPH. Some patients have predominant epithelial hyperplasia and others have predominant stromal hyperplasia. Those with stromal hyperplasia may have collagen or smooth muscle predominance. Patients with epithelial predominance best respond to treatment with finasteride.

(Choice B, C & D) Alpha-1 blockers produce symptomatic improvement in patients with BPH by their action on smooth muscles present in prostate and bladder base. Patients with smooth muscle predominance best respond to treatment with alpha-1 blockers. Patients with collagen predominance respond neither to finasteride nor to alpha-1 blockers.

Educational objective:
Finasteride acts on epithelium and alpha-1 blockers act on smooth muscles of prostate and bladder base.

Pharmacology	Male Reproductive System	Benign prostatic hyperplasia
Subject	System	Topic

Copyright © UWorld. All rights reserved.

A 75-year-old man comes to the office due to 4 weeks of increased urinary hesitancy and progressive low back pain. Spinal imaging reveals multiple lesions suspicious for metastatic cancer. Biopsy of a bone lesion shows well-differentiated adenocarcinoma. Treatment with a medication that does which of the following would most likely reduce the spread of this patient's cancer?

A. Activation of the androgen receptor

B. Activation of the LH receptor

C. Blockade of the estrogen receptor

D. Blockade of the FSH receptor

E. Inhibition of the 17-alpha-hydroxylase enzyme

Submit

A 75-year-old man comes to the office due to 4 weeks of increased urinary hesitancy and progressive low back pain. Spinal imaging reveals multiple lesions suspicious for metastatic cancer. Biopsy of a bone lesion shows well-differentiated adenocarcinoma. Treatment with a medication that does which of the following would most likely reduce the spread of this patient's cancer?

A. Activation of the androgen receptor (9%)

B. Activation of the LH receptor (12%)

C. Blockade of the estrogen receptor (5%)

D. Blockade of the FSH receptor (20%)

✓ E. Inhibition of the 17-alpha-hydroxylase enzyme (52%)

Omitted
Correct answer
E

52%
Answered correctly

03 secs
Time Spent

04/19/2020
Last Updated

Explanation

Effect of 17α-hydroxylase inhibitors on adrenal steroidogenesis

Zona glomerulosa	Zona fasciculata	Zona reticularis
Cholesterol		
Side chain cleavage enzyme		

Effect of 17α-hydroxylase inhibitors on adrenal steroidogenesis

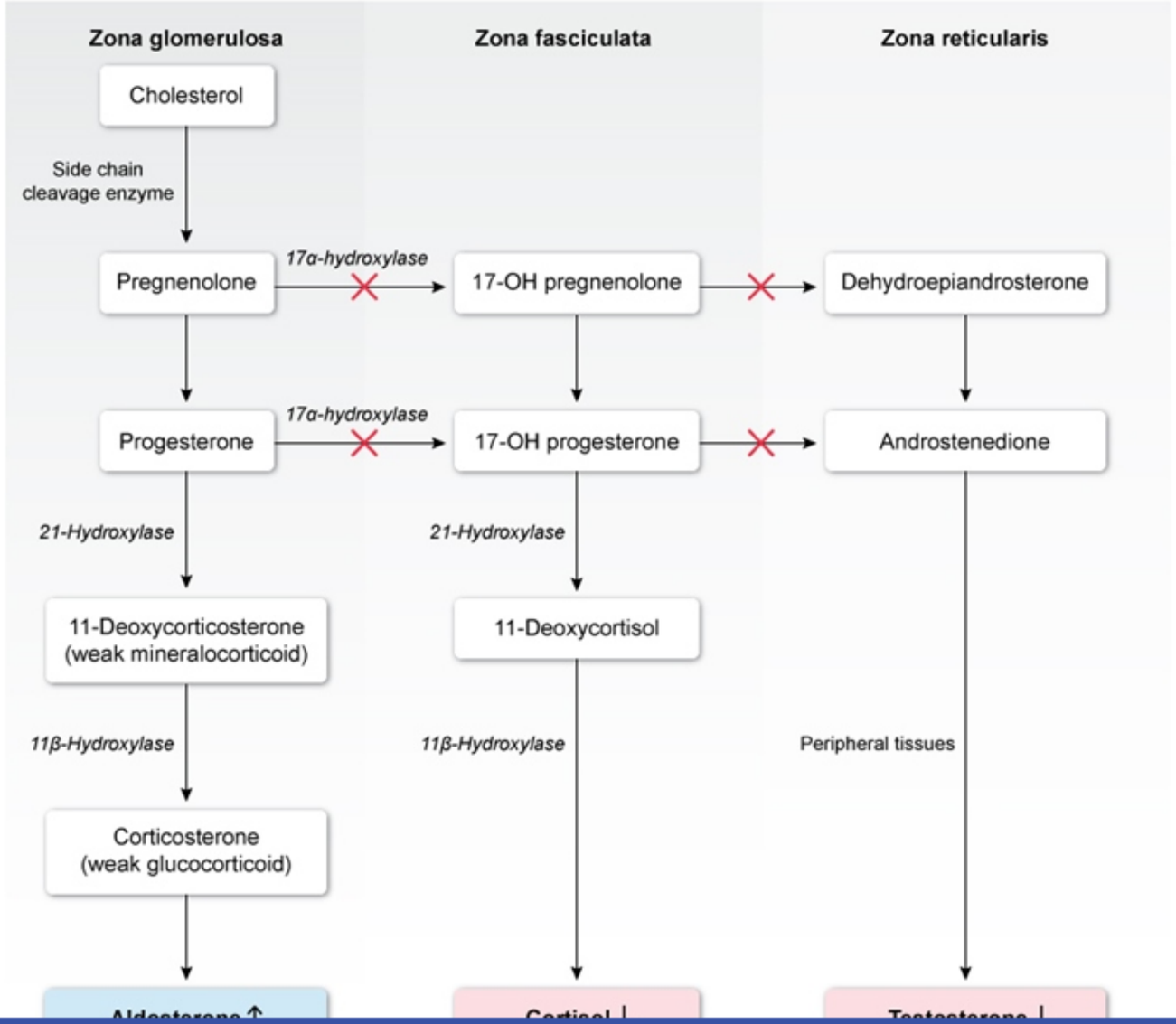

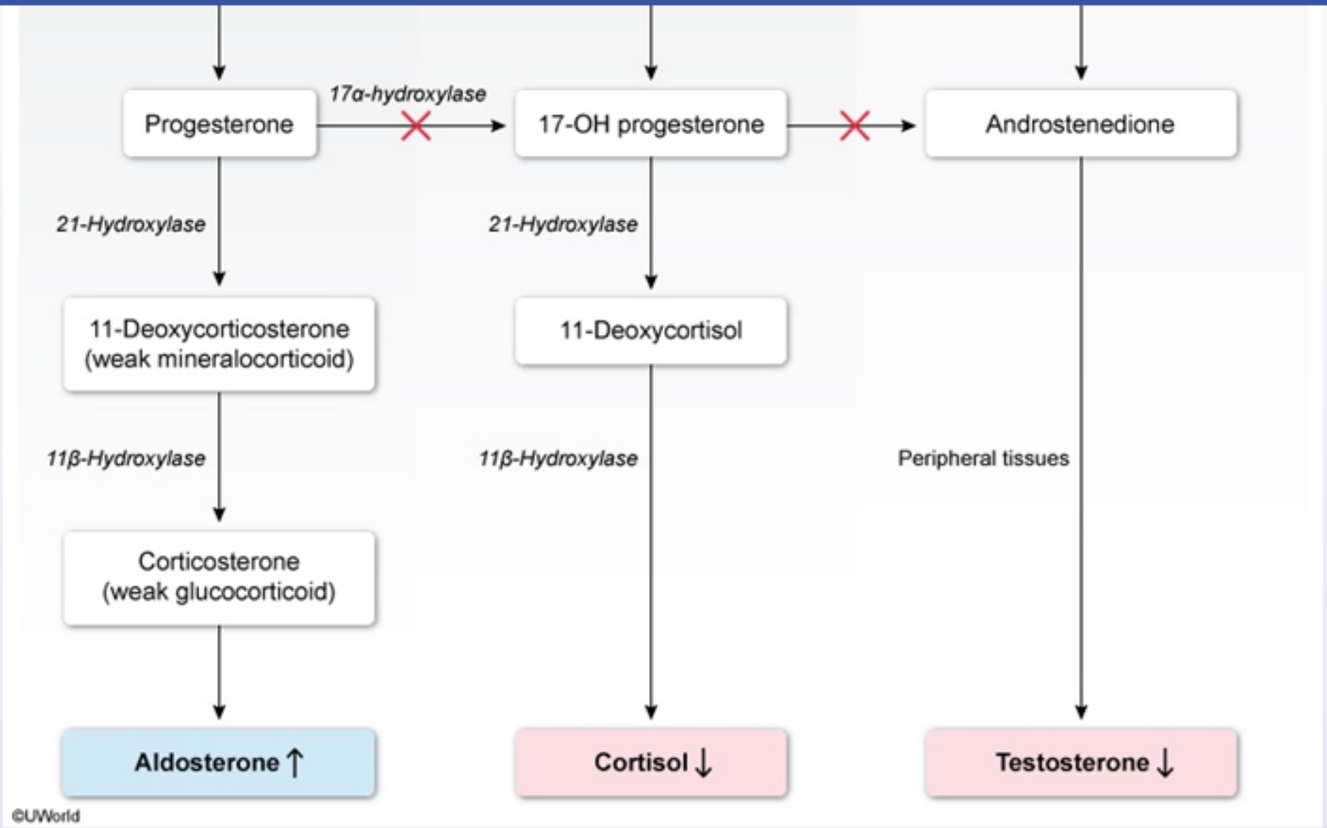

This older patient with urinary hesitancy and multiple bone lesions has biopsy evidence of well-differentiated adenocarcinoma, raising strong suspicion for **metastatic prostate adenocarcinoma**. Prostate cancer is the most common non-skin cancer in men; it has a predilection for metastases to **bone** due to tumor surface proteins that bind to pericytes and bone marrow stromal cells.

Prostate adenocarcinoma is generally an **androgen-sensitive tumor**. Because androgens in men are produced primarily in the testes, initial treatment for advanced disease usually involves medical or surgical orchiectomy to eliminate testicular production of androgens. However, androgens are also produced in the adrenal glands and tumor cells via the expression of **17-alpha-hydroxylase**, a cytochrome P-450 enzyme that converts pregnenolone/progesterone into dehydroepiandrosterone **(DHEA)/androstenedione**. Because these extratesticular androgens can also drive tumor growth, patients with advanced disease and those with castration-resistant prostate cancer generally receive **abiraterone**, a

This older patient with urinary hesitancy and multiple bone lesions has biopsy evidence of well-differentiated adenocarcinoma, raising strong suspicion for **metastatic prostate adenocarcinoma**. Prostate cancer is the most common non-skin cancer in men; it has a predilection for metastases to **bone** due to tumor surface proteins that bind to pericytes and bone marrow stromal cells.

Prostate adenocarcinoma is generally an **androgen-sensitive tumor**. Because androgens in men are produced primarily in the testes, initial treatment for advanced disease usually involves medical or surgical orchiectomy to eliminate testicular production of androgens. However, androgens are also produced in the adrenal glands and tumor cells via the expression of **17-alpha-hydroxylase**, a cytochrome P-450 enzyme that converts pregnenolone/progesterone into dehydroepiandrosterone **(DHEA)**/**androstenedione**. Because these extratesticular androgens can also drive tumor growth, patients with advanced disease and those with castration-resistant prostate cancer generally receive **abiraterone**, a medication that irreversibly **inhibits 17-alpha-hydroxylase**. This limits extratesticular androgen production, which slows the growth of the tumor.

(Choice A) Because prostate cancer is an androgen-sensitive tumor, activation of the androgen receptor would worsen the disease.

(Choice B) LH triggers Leydig cells in the testes to produce androgens. Therefore, activation of the LH receptor would worsen prostate cancer (increased androgen production). Medical orchiectomy involves the administration of GnRH analogues, which reduce LH levels by eliminating the pulsatile stimulation of pituitary gonadotrophs.

(Choice C) Estrogen receptor blockade is used in the treatment of estrogen-sensitive breast and endometrial cancer. Prostate cancer is driven by androgens such as testosterone and DHEA, not estrogen.

(Choice D) FSH induces spermatogenesis in men; LH is responsible for testicular androgen production. Therefore, blockade of FSH would not inhibit systemic androgen generation.

Educational objective:
Patients with advanced or castration-resistant prostate cancer are often treated with an 17-alpha-hydroxylase inhibitors (eg, abiraterone), which block the generation of androgens in the adrenal glands, testes, and tumor cells. This reduces systemic androgen levels, which limit prostate cancer growth.

Pharmacology	Male Reproductive System	Prostate cancer
Subject	System	Topic

suspicion for **metastatic prostate adenocarcinoma**. Prostate cancer is the most common non-skin cancer in men; it has a predilection for metastases to **bone** due to tumor surface proteins that bind to pericytes and bone marrow stromal cells.

Prostate adenocarcinoma is generally an **androgen-sensitive tumor**. Because androgens in men are produced primarily in the testes, initial treatment for advanced disease usually involves medical or surgical orchiectomy to eliminate testicular production of androgens. However, androgens are also produced in the adrenal glands and tumor cells via the expression of **17-alpha-hydroxylase**, a cytochrome P-450 enzyme that converts pregnenolone/progesterone into dehydroepiandrosterone **(DHEA)/androstenedione**. Because these extratesticular androgens can also drive tumor growth, patients with advanced disease and those with castration-resistant prostate cancer generally receive **abiraterone**, a medication that irreversibly **inhibits 17-alpha-hydroxylase**. This limits extratesticular androgen production, which slows the growth of the tumor.

(Choice A) Because prostate cancer is an androgen-sensitive tumor, activation of the androgen receptor would worsen the disease.

(Choice B) LH triggers Leydig cells in the testes to produce androgens. Therefore, activation of the LH receptor would worsen prostate cancer (increased androgen production). Medical orchiectomy involves the administration of GnRH analogues, which reduce LH levels by eliminating the pulsatile stimulation of pituitary gonadotrophs.

(Choice C) Estrogen receptor blockade is used in the treatment of estrogen-sensitive breast and endometrial cancer. Prostate cancer is driven by androgens such as testosterone and DHEA, not estrogen.

(Choice D) FSH induces spermatogenesis in men; LH is responsible for testicular androgen production. Therefore, blockade of FSH would not inhibit systemic androgen generation.

Educational objective:
Patients with advanced or castration-resistant prostate cancer are often treated with an 17-alpha-hydroxylase inhibitors (eg, abiraterone), which block the generation of androgens in the adrenal glands, testes, and tumor cells. This reduces systemic androgen levels, which limit prostate cancer growth.

Pharmacology	Male Reproductive System	Prostate cancer
Subject	System	Topic

Copyright © UWorld. All rights reserved.

A 2-day-old girl is in the newborn nursery with persistent crying, tremors, tachypnea, sneezing, and diarrhea. She was born vaginally and had been breastfeeding well until several hours ago when she became tachypneic. Her mother has poorly controlled schizophrenia and did not receive prenatal care. The patient's mother also had a positive hepatitis C antibody test during postnatal laboratory testing. On physical examination, the girl has increased tone in all extremities. She is irritable during examination but quiets when swaddled. Chest radiograph shows normal lung fields. Which of the following is the most appropriate pharmacotherapy for treatment of the newborn's symptoms?

- A. Flumazenil
- B. Folic acid
- C. Methadone
- D. Naloxone
- E. Sodium bicarbonate
- F. Vitamin K

Submit

A 2-day-old girl is in the newborn nursery with persistent crying, tremors, tachypnea, sneezing, and diarrhea. She was born vaginally and had been breastfeeding well until several hours ago when she became tachypneic. Her mother has poorly controlled schizophrenia and did not receive prenatal care. The patient's mother also had a positive hepatitis C antibody test during postnatal laboratory testing. On physical examination, the girl has increased tone in all extremities. She is irritable during examination but quiets when swaddled. Chest radiograph shows normal lung fields. Which of the following is the most appropriate pharmacotherapy for treatment of the newborn's symptoms?

A. Flumazenil (11%)
B. Folic acid (4%)
✓ C. Methadone (44%)
D. Naloxone (17%)
E. Sodium bicarbonate (12%)
F. Vitamin K (8%)

Omitted
Correct answer
C

44%
Answered correctly

02 secs
Time Spent

01/25/2020
Last Updated

Explanation

Neonatal abstinence syndrome	
Pathophysiology	• Withdrawal from transplacental opiates due to maternal drug use

Neonatal abstinence syndrome	
Pathophysiology	• Withdrawal from transplacental opiates due to maternal drug use
Clinical manifestations	• **Neurologic:** Irritability, hypertonia, jittery movements, seizures (rare) • **Gastrointestinal:** Diarrhea, vomiting, feeding intolerance • **Autonomic:** Sweating, sneezing, pupillary dilation
Treatment	• Opioid therapy (eg, morphine, methadone)

This newborn is showing signs of **neonatal abstinence syndrome (NAS)** due to withdrawal from **opiates**. NAS can result from illicit maternal drug use or prescribed opiate use (ie, a drug treatment program). At-risk newborns include those born to mothers with poor mental health, no prenatal care, and hepatitis C infection, as in this case.

NAS typically presents a variety of manifestations, as shown in the Table. This newborn's crying, tremors, **tachypnea**, sneezing, **irritability**, and **diarrhea** are classic for NAS. Jittery movements are also common in affected newborns. The onset of symptoms depends on the type of opiate(s) used and how recently used by the mother before delivery. Generally, newborns exposed to drugs with shorter half-lives (eg, heroin) are symptomatic at age 1-2 days; those exposed to drugs with longer half-lives (eg, methadone) may present later.

The treatment of choice for acute opioid withdrawal in neonates is opiate replacement, usually **morphine** or **methadone**. The dose is gradually increased until symptoms are controlled, and then the patient is weaned off over several weeks.

(Choice A) Benzodiazepine toxicity presents primarily with depression of the central nervous system. Flumazenil is a gamma-aminobutyric acid (GABA) receptor antagonist used for benzodiazepine reversal.

(Choice B) Supplementation with folic acid can help prevent neural tube defects during pregnancy.

(Choice D) Naloxone is a pure opioid receptor antagonist. It is used in the setting of acute opioid intoxication or overdose and for diagnosing opioid dependence. Administering naloxone to a patient with opioid withdrawal can result in more severe withdrawal symptoms and potentially cause seizures.

(Choice E) Sodium bicarbonate is used to treat the overdose of tricyclic antidepressants (eg, amitriptyline).

opiate(s) used and how recently used by the mother before delivery. Generally, newborns exposed to drugs with shorter half-lives (eg, heroin) are symptomatic at age 1-2 days; those exposed to drugs with longer half-lives (eg, methadone) may present later.

The treatment of choice for acute opioid withdrawal in neonates is opiate replacement, usually **morphine** or **methadone**. The dose is gradually increased until symptoms are controlled, and then the patient is weaned off over several weeks.

(Choice A) Benzodiazepine toxicity presents primarily with depression of the central nervous system. Flumazenil is a gamma-aminobutyric acid (GABA) receptor antagonist used for benzodiazepine reversal.

(Choice B) Supplementation with folic acid can help prevent neural tube defects during pregnancy.

(Choice D) Naloxone is a pure opioid receptor antagonist. It is used in the setting of acute opioid intoxication or overdose and for diagnosing opioid dependence. Administering naloxone to a patient with opioid withdrawal can result in more severe withdrawal symptoms and potentially cause seizures.

(Choice E) Sodium bicarbonate is used to treat the overdose of tricyclic antidepressants (eg, amitriptyline).

(Choice F) Vitamin K is used primarily as a reversal agent for the anticoagulant warfarin and to prevent hemorrhagic disease of the newborn. It would not help improve this patient's current symptoms.

Educational objective:
Neonatal abstinence syndrome presents with neurologic, gastrointestinal, and autonomic symptoms. Tremors, irritability, diarrhea, and poor feeding are classic findings. Opiate replacement therapy is the treatment of choice; the dose is titrated to the patient's symptoms, and the patient is then slowly weaned.

References

- Neonatal abstinence syndrome.
- Neonatal opioid withdrawal syndrome.

Pharmacology	Pregnancy, Childbirth & Puerperium	Opioids
Subject	System	Topic

A 66-year-old man comes to the office for follow-up of metastatic prostate cancer. He was diagnosed 12 months ago, when he was found to have a single bony metastasis. The patient declined orchiectomy and was treated with a long-acting gonadotropin-releasing hormone agonist. While on this therapy, he developed nocturnal pain in the area of the bony metastasis and was found to have a rising level of prostate-specific antigen. Flutamide was then added to his initial therapy and led to significant pain relief and a decrease in the size of the primary tumor. Which of the following mechanisms is the best explanation for the effects of flutamide in this patient?

A. Decreased androgen aromatization

B. Decreased Leydig cell stimulation

C. Decreased peripheral androgen conversion

D. Impaired androgen-receptor interaction

E. Inhibition of androgen synthesis

Submit

A 66-year-old man comes to the office for follow-up of metastatic prostate cancer. He was diagnosed 12 months ago, when he was found to have a single bony metastasis. The patient declined orchiectomy and was treated with a long-acting gonadotropin-releasing hormone agonist. While on this therapy, he developed nocturnal pain in the area of the bony metastasis and was found to have a rising level of prostate-specific antigen. Flutamide was then added to his initial therapy and led to significant pain relief and a decrease in the size of the primary tumor. Which of the following mechanisms is the best explanation for the effects of flutamide in this patient?

- A. Decreased androgen aromatization (7%)
- B. Decreased Leydig cell stimulation (5%)
- C. Decreased peripheral androgen conversion (21%)
- ✓ D. Impaired androgen-receptor interaction (56%)
- E. Inhibition of androgen synthesis (9%)

Omitted
Correct answer
D

56%
Answered correctly

02 secs
Time Spent

02/01/2020
Last Updated

Explanation

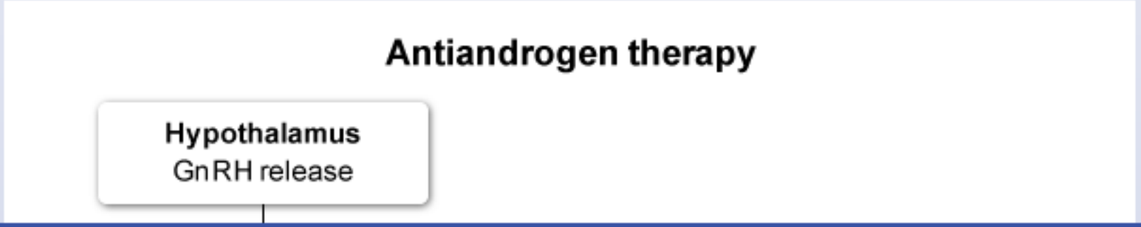

Antiandrogen therapy

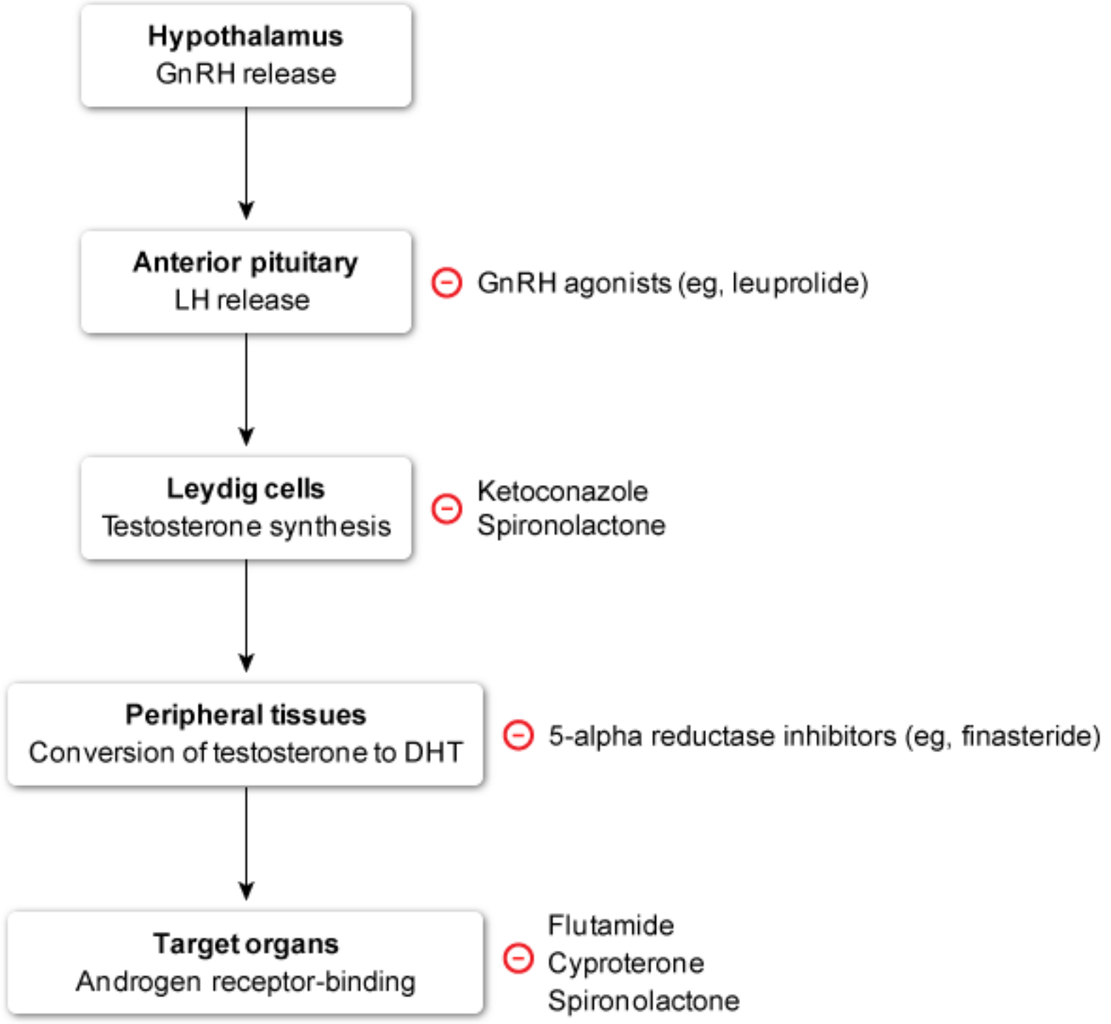

DHT = dihydrotestosterone

©UWorld

Prostate cancer is **testosterone-dependent** and can be treated in most cases with surgical and/or pharmacologic androgen deprivation. Initial options include bilateral orchiectomy or a gonadotropin-releasing hormone (GnRH) agonist. **Pulsatile** release of GnRH from the hypothalamus stimulates secretion of LH from the anterior pituitary and leads to increased testosterone production. However, **constant** GnRH activity causes down-regulation of the GnRH receptors on pituitary gonadotrophin cells, which suppresses LH secretion. Therefore, long-acting GnRH agonists (eg, leuprolide) paradoxically cause a decrease in testicular Leydig cell stimulation **(Choice B)**. The use of long-acting GnRH agonists can be associated with a **transient** rise in LH and testosterone levels following treatment initiation. As a result, antiandrogens are sometimes prescribed concurrently to limit the tumor-stimulating effects of this initial testosterone rise.

Flutamide is a nonsteroid agent that acts as a **competitive testosterone receptor inhibitor**. Prevention of androgen-receptor binding blocks the stimulatory effect of androgens on the primary tumor and metastases and leads to a reduction in their size (improving symptoms such as bone pain and urinary obstruction).

(Choice A) Aromatase inhibitors (eg, anastrozole) decrease the peripheral conversion of androgens to estrogen and are used in postmenopausal women with estrogen receptor-positive breast cancer. They do not lower androgen levels and are not used in the treatment of prostate cancer.

(Choice C) Finasteride decreases peripheral conversion of testosterone to dihydrotestosterone by inhibiting 5-α-reductase. It is used for treatment of benign prostatic hyperplasia and male-pattern baldness.

(Choice E) Ketoconazole is a weak antiandrogen that decreases synthesis of steroid hormones in the gonads and adrenals. Flutamide does not inhibit testosterone production by Leydig cells.

Educational objective:
Flutamide is a nonsteroid anti-androgen that acts as a competitive inhibitor of testosterone receptors. It is used in combination with long-acting gonadotropin-releasing hormone agonists for the treatment of prostate cancer.

References

- Non-steroidal antiandrogen monotherapy compared with luteinizing hormone-releasing hormone agonists or surgical castration monotherapy for advanced prostate cancer: a Cochrane systematic review.
- Combined androgen blockade in advanced prostate cancer: looking back to move forward.

(eg, leuprolide) paradoxically cause a decrease in testicular Leydig cell stimulation **(Choice B)**. The use of long-acting GnRH agonists can be associated with a **transient** rise in LH and testosterone levels following treatment initiation. As a result, antiandrogens are sometimes prescribed concurrently to limit the tumor-stimulating effects of this initial testosterone rise.

Flutamide is a nonsteroid agent that acts as a **competitive testosterone receptor inhibitor**. Prevention of androgen-receptor binding blocks the stimulatory effect of androgens on the primary tumor and metastases and leads to a reduction in their size (improving symptoms such as bone pain and urinary obstruction).

(Choice A) Aromatase inhibitors (eg, anastrozole) decrease the peripheral conversion of androgens to estrogen and are used in postmenopausal women with estrogen receptor-positive breast cancer. They do not lower androgen levels and are not used in the treatment of prostate cancer.

(Choice C) Finasteride decreases peripheral conversion of testosterone to dihydrotestosterone by inhibiting 5-α-reductase. It is used for treatment of benign prostatic hyperplasia and male-pattern baldness.

(Choice E) Ketoconazole is a weak antiandrogen that decreases synthesis of steroid hormones in the gonads and adrenals. Flutamide does not inhibit testosterone production by Leydig cells.

Educational objective:
Flutamide is a nonsteroid anti-androgen that acts as a competitive inhibitor of testosterone receptors. It is used in combination with long-acting gonadotropin-releasing hormone agonists for the treatment of prostate cancer.

References

- Non-steroidal antiandrogen monotherapy compared with luteinizing hormone-releasing hormone agonists or surgical castration monotherapy for advanced prostate cancer: a Cochrane systematic review.
- Combined androgen blockade in advanced prostate cancer: looking back to move forward.

Pharmacology	Male Reproductive System	Prostate cancer
Subject	System	Topic

Copyright © UWorld. All rights reserved.

A 55-year-old woman is diagnosed with breast cancer and undergoes breast-sparing mastectomy. The tumor margin did not show any invasion, and sentinel axillary lymph node biopsy was negative for nodal metastasis. The tumor was estrogen receptor and progesterone receptor positive but HER-2 negative. After discussion of management options, the patient is started on tamoxifen. While on this medication, she experiences hot flashes that come and go in waves and affect her sleep significantly. Which of the following conditions is the patient also likely to experience as a result of this therapy?

A. Decrease in bone mass

B. Decrease in HDL level

C. Endometrial hyperplasia

D. Fibroadenoma of the breast

E. Increase in LDL level

Submit

A 55-year-old woman is diagnosed with breast cancer and undergoes breast-sparing mastectomy. The tumor margin did not show any invasion, and sentinel axillary lymph node biopsy was negative for nodal metastasis. The tumor was estrogen receptor and progesterone receptor positive but HER-2 negative. After discussion of management options, the patient is started on tamoxifen. While on this medication, she experiences hot flashes that come and go in waves and affect her sleep significantly. Which of the following conditions is the patient also likely to experience as a result of this therapy?

A. Decrease in bone mass (22%)

B. Decrease in HDL level (1%)

✓ C. Endometrial hyperplasia (72%)

D. Fibroadenoma of the breast (0%)

E. Increase in LDL level (2%)

Omitted
Correct answer
C

72%
Answered correctly

02 secs
Time Spent

05/10/2020
Last Updated

Explanation

Selective estrogen receptor modulators	
Drugs	• Tamoxifen • Raloxifene
	• Competitive inhibitor of estrogen binding

Selective estrogen receptor modulators	
Drugs	• Tamoxifen • Raloxifene
Mechanism of action	• Competitive inhibitor of estrogen binding • Mixed agonist/antagonist action
Indications	• Prevention of breast cancer in high-risk patients • Tamoxifen: adjuvant treatment of breast cancer • Raloxifene: postmenopausal osteoporosis
Adverse effects	• Hot flashes • Venous thromboembolism • Endometrial hyperplasia & carcinoma (tamoxifen only)

Tamoxifen and raloxifene are **selective estrogen receptor modulators** (SERMs). They interact with the estrogen receptor and have agonist or antagonist activity depending on the tissue. In breast tissue, tamoxifen has an anti-estrogenic effect, and it is used for adjuvant treatment of estrogen receptor-positive **breast cancer**. Tamoxifen reduces the risk of recurrent cancer as well as estrogen-dependent benign breast lesions (eg, fibroadenoma, cystic changes) **(Choice D)**.

In endometrial tissue, however, tamoxifen has a stimulatory effect and can lead to development of **endometrial hyperplasia** and endometrial cancer. This risk is not seen with raloxifene.

(Choice A) Tamoxifen and raloxifene act as partial estrogen receptor agonists in bone and can cause an increase in bone mineral density after menopause.

(Choices B and E) Tamoxifen has a favorable effect on serum lipids, with a decrease in total and LDL cholesterol and no significant change in HDL. Serum triglycerides may increase in some patients.

Educational objective:
Selective estrogen receptor modulators (eg, tamoxifen, raloxifene) are competitive inhibitors of estrogen binding to estrogen receptors. They can

Adverse effects	• Hot flashes • Venous thromboembolism • Endometrial hyperplasia & carcinoma (tamoxifen only)

Tamoxifen and raloxifene are **selective estrogen receptor modulators** (SERMs). They interact with the estrogen receptor and have agonist or antagonist activity depending on the tissue. In breast tissue, tamoxifen has an anti-estrogenic effect, and it is used for adjuvant treatment of estrogen receptor-positive **breast cancer**. Tamoxifen reduces the risk of recurrent cancer as well as estrogen-dependent benign breast lesions (eg, fibroadenoma, cystic changes) **(Choice D)**.

In endometrial tissue, however, tamoxifen has a stimulatory effect and can lead to development of **endometrial hyperplasia** and endometrial cancer. This risk is not seen with raloxifene.

(Choice A) Tamoxifen and raloxifene act as partial estrogen receptor agonists in bone and can cause an increase in bone mineral density after menopause.

(Choices B and E) Tamoxifen has a favorable effect on serum lipids, with a decrease in total and LDL cholesterol and no significant change in HDL. Serum triglycerides may increase in some patients.

Educational objective:
Selective estrogen receptor modulators (eg, tamoxifen, raloxifene) are competitive inhibitors of estrogen binding to estrogen receptors. They can have agonist or antagonist effects depending on the specific tissue. Tamoxifen has an estrogenic effect on the uterus and can cause endometrial hyperplasia and cancer.

References

- Tamoxifen treatment for breast cancer and risk of endometrial cancer: a case-control study.

Pharmacology	Female Reproductive System & Breast	Breast cancer
Subject	System	Topic

Copyright © UWorld. All rights reserved.

A 68-year-old man comes to the office for follow-up. The patient underwent radical prostatectomy for prostate adenocarcinoma 6 months ago, which decreased his serum prostate-specific antigen (PSA) level from 16 ng/mL at the time of surgery to 1 ng/mL 6 weeks after surgery. Initial staging evaluation revealed no evidence of metastatic disease. PSA level is now 8 ng/dL, and repeat imaging reveals regional lymphadenopathy. The patient is prescribed combination therapy with buserelin and bicalutamide. Which of the following is the main reason for adding bicalutamide to this patient's treatment regimen?

A. To block androgen production from adrenal glands

B. To induce apoptotic death of cancer cells

C. To prevent sexual dysfunction from buserelin therapy

D. To prevent testosterone surge effect from buserelin therapy

E. To prevent vasomotor symptoms from buserelin therapy

Submit

A 68-year-old man comes to the office for follow-up. The patient underwent radical prostatectomy for prostate adenocarcinoma 6 months ago, which decreased his serum prostate-specific antigen (PSA) level from 16 ng/mL at the time of surgery to 1 ng/mL 6 weeks after surgery. Initial staging evaluation revealed no evidence of metastatic disease. PSA level is now 8 ng/dL, and repeat imaging reveals regional lymphadenopathy. The patient is prescribed combination therapy with buserelin and bicalutamide. Which of the following is the main reason for adding bicalutamide to this patient's treatment regimen?

- A. To block androgen production from adrenal glands (19%)
- B. To induce apoptotic death of cancer cells (5%)
- C. To prevent sexual dysfunction from buserelin therapy (5%)
- ✓ D. To prevent testosterone surge effect from buserelin therapy (60%)
- E. To prevent vasomotor symptoms from buserelin therapy (9%)

Omitted
Correct answer
D

60%
Answered correctly

02 secs
Time Spent

04/17/2020
Last Updated

Explanation

Prostate cancer is an **androgen-dependent** tumor early in the disease course. Because androgens in men are primarily made in the testes, patients with recurrent (eg, rising prostate-specific antigen level after prostatectomy) or disseminated (eg, regional lymphadenopathy) prostate cancer are generally treated with surgical or **medical orchiectomy** to reduce systemic androgen levels, thereby reducing the primary growth factor for the tumor.

Androgen production in men is controlled by the hypothalamic-pituitary-testicular axis. **GnRH** is secreted by the hypothalamus in a **pulsatile**

Explanation

Prostate cancer is an **androgen-dependent** tumor early in the disease course. Because androgens in men are primarily made in the testes, patients with recurrent (eg, rising prostate-specific antigen level after prostatectomy) or disseminated (eg, regional lymphadenopathy) prostate cancer are generally treated with surgical or **medical orchiectomy** to reduce systemic androgen levels, thereby reducing the primary growth factor for the tumor.

Androgen production in men is controlled by the hypothalamic-pituitary-testicular axis. **GnRH** is secreted by the hypothalamus in a **pulsatile** fashion, which stimulates pituitary gonadotrophs to release luteinizing hormone (LH); LH then stimulates the Leydig cells of the testes to generate and **secrete androgens**. Patients who undergo medical orchiectomy are often treated with a GnRH analogue (eg, **buserelin**), which stimulates the pituitary gland in a **continuous** fashion, leading to a down-regulation of the GnRH receptor. This subsequently drops LH secretion, which **lowers androgen production** by the testes.

However, because GnRH analogues **temporarily activate** the GnRH receptor prior to downregulation, patients often develop a **surge in androgens** during the first few weeks of therapy. Therefore, androgen-receptor inhibitors (eg, **bicalutamide**) are usually concurrently administered during the first weeks of GnRH analogue therapy to block the activity of androgens on the tumor cells.

(Choice A) Although adrenal synthesis of androgens is not an initial target in prostate cancer, patients who have progressive disease despite medical or surgical orchiectomy are often treated with abiraterone, which limits androgen production in the tumor, adrenal gland, and testes by inhibiting the enzyme 17alpha-hydroxylase.

(Choice B) Chemotherapy is often administered with GnRH analogues in patients with metastatic prostate cancer to induce cancer cell death. However, bicalutamide is an androgen-receptor inhibitor, not a chemotherapy agent.

(Choice C) Sexual dysfunction occurs in the majority of men given GnRH analogues due to reduced libido and erectile dysfunction. This can be managed with phosphodiesterase inhibitors.

(Choice E) GnRH analogues often cause vasomotor symptoms (hot flashes) due to estrogen withdrawal. Treatment is similar to menopausal hot flashes in women; progesterone, cyproterone, and selective serotonin reuptake inhibitors are somewhat effective.

Educational objective:
Because prostate cancer is an androgen-dependent tumor, patients with advanced disease are generally treated with surgical or medical

and **secrete androgens**. Patients who undergo medical orchiectomy are often treated with a GnRH analogue (eg, **buserelin**), which stimulates the pituitary gland in a **continuous** fashion, leading to a down-regulation of the GnRH receptor. This subsequently drops LH secretion, which **lowers androgen production** by the testes.

However, because GnRH analogues **temporarily activate** the GnRH receptor prior to downregulation, patients often develop a **surge in androgens** during the first few weeks of therapy. Therefore, androgen-receptor inhibitors (eg, **bicalutamide**) are usually concurrently administered during the first weeks of GnRH analogue therapy to block the activity of androgens on the tumor cells.

(Choice A) Although adrenal synthesis of androgens is not an initial target in prostate cancer, patients who have progressive disease despite medical or surgical orchiectomy are often treated with abiraterone, which limits androgen production in the tumor, adrenal gland, and testes by inhibiting the enzyme 17alpha-hydroxylase.

(Choice B) Chemotherapy is often administered with GnRH analogues in patients with metastatic prostate cancer to induce cancer cell death. However, bicalutamide is an androgen-receptor inhibitor, not a chemotherapy agent.

(Choice C) Sexual dysfunction occurs in the majority of men given GnRH analogues due to reduced libido and erectile dysfunction. This can be managed with phosphodiesterase inhibitors.

(Choice E) GnRH analogues often cause vasomotor symptoms (hot flashes) due to estrogen withdrawal. Treatment is similar to menopausal hot flashes in women; progesterone, cyproterone, and selective serotonin reuptake inhibitors are somewhat effective.

Educational objective:
Because prostate cancer is an androgen-dependent tumor, patients with advanced disease are generally treated with surgical or medical orchiectomy. Medical orchiectomy uses GnRH analogues to reduce LH production, which subsequently reduces androgen production in the testes. Because there is an initial surge in androgens at the start of therapy (due to stimulation of the GnRH receptor), patients prescribed GnRH therapy are usually treated with a few weeks of androgen-receptor inhibitors (eg, bicalutamide).

Pharmacology	Male Reproductive System	Prostate cancer
Subject	System	Topic

Copyright © UWorld. All rights reserved.

A newborn boy is in the neonatal intensive care unit for mechanical ventilation due to pulmonary hypoplasia. He was born vaginally to a 41-year-old woman who did not establish prenatal care until 30 weeks gestation. The mother had assumed her lack of periods was due to early menopause, which runs in her family. She took many different medications for her poorly controlled hypertension over the past year before realizing she was pregnant. Prenatal ultrasonography demonstrated severe oligohydramnios for which delivery was induced. Examination of the infant shows an intubated and sedated boy with weight at the 3rd percentile. His temporal, occipital, and parietal bones are underdeveloped, and his right lower limb is shortened and contracted. Which of the following is the most likely cause of this neonate's abnormalities?

A. Alpha 2-adrenergic agonism
B. Beta-adrenergic receptor blockade
C. Cellular damage from free radicals
D. Impaired metabolism of angiotensin I
E. Impaired oxygen delivery
F. Impaired prostaglandin metabolism

Submit

A newborn boy is in the neonatal intensive care unit for mechanical ventilation due to pulmonary hypoplasia. He was born vaginally to a 41-year-old woman who did not establish prenatal care until 30 weeks gestation. The mother had assumed her lack of periods was due to early menopause, which runs in her family. She took many different medications for her poorly controlled hypertension over the past year before realizing she was pregnant. Prenatal ultrasonography demonstrated severe oligohydramnios for which delivery was induced. Examination of the infant shows an intubated and sedated boy with weight at the 3rd percentile. His temporal, occipital, and parietal bones are underdeveloped, and his right lower limb is shortened and contracted. Which of the following is the most likely cause of this neonate's abnormalities?

- A. Alpha 2-adrenergic agonism (2%)
- B. Beta-adrenergic receptor blockade (8%)
- C. Cellular damage from free radicals (6%)
- ✓ D. Impaired metabolism of angiotensin I (60%)
- E. Impaired oxygen delivery (14%)
- F. Impaired prostaglandin metabolism (8%)

Omitted
Correct answer
D

60%
Answered correctly

03 secs
Time Spent

02/21/2020
Last Updated

Explanation

Potter sequence

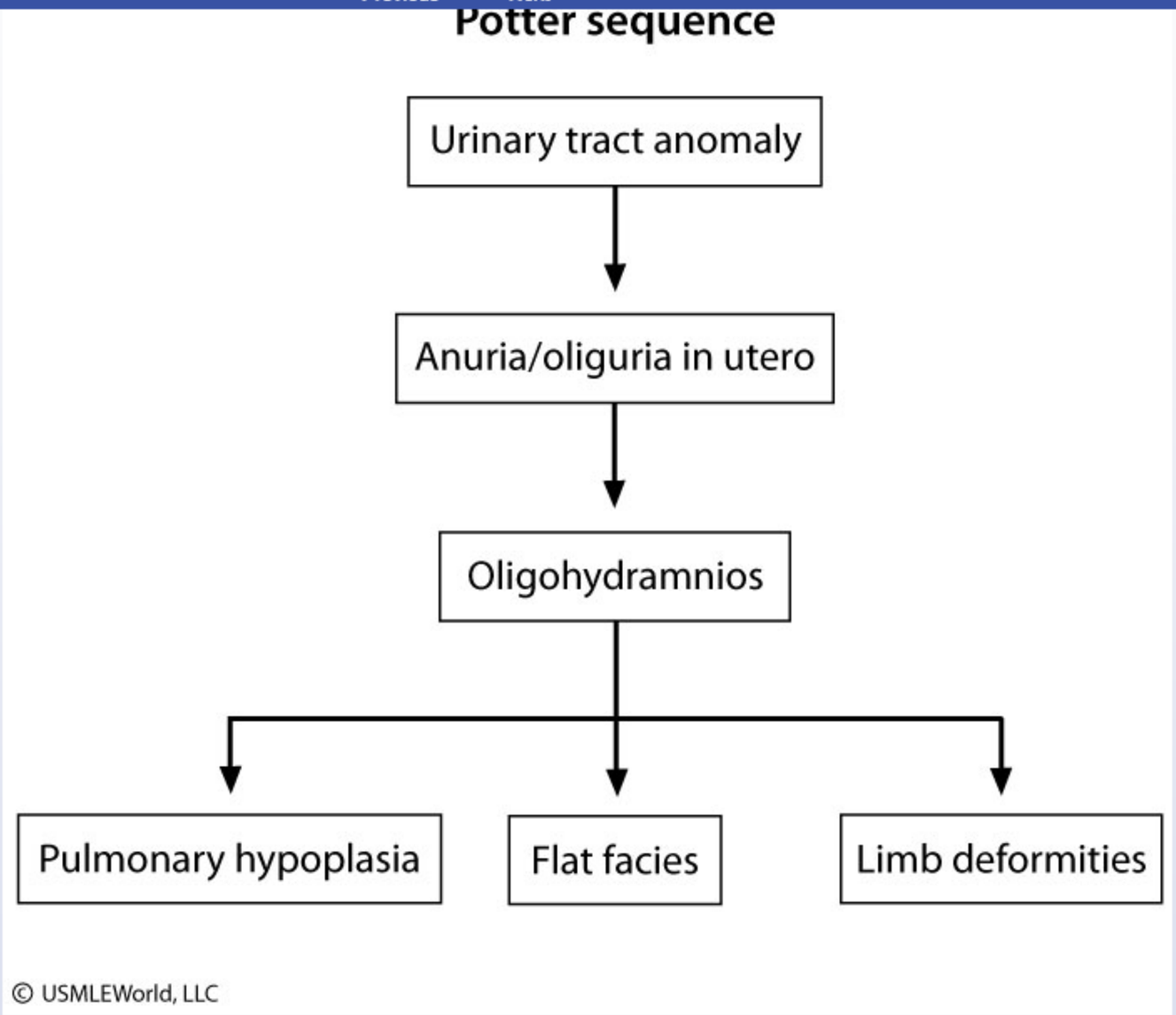

The constellation of findings in this neonate is likely due to maternal use of angiotensin-converting enzyme **(ACE) inhibitors** and/or angiotensin II

The constellation of findings in this neonate is likely due to maternal use of angiotensin-converting enzyme **(ACE) inhibitors** and/or angiotensin II receptor blockers **(ARBs)** during pregnancy for antihypertensive therapy. Angiotensin II is required for normal renal development. ACE inhibitors prevent the conversion of angiotensin I to II, whereas ARBs block the action of angiotensin II at the AT1 receptor.

Fetal urine is a major source of amniotic fluid, a liquid that surrounds and cushions the fetus and permits normal lung development. **Low angiotensin II** levels can result in fetal renal maldevelopment, which in turn leads to reduced diuresis and **oligohydramnios**. Severe oligohydramnios can result in pulmonary hypoplasia and skeletal defects. In addition, low angiotensin II levels may result in impaired cranial vascularization and **hypocalvaria** (hypoplasia of skull bones).

(Choices A and B) Methyldopa, an alpha 2-adrenergic agonist, and labetalol, a beta-adrenergic antagonist, are first-line antihypertensive medications in pregnancy. Although labetalol can cause fetal/neonatal bradycardia, hypoglycemia, and hypotension, neither medication causes congenital malformations. Instead, fetal outcomes are improved by reducing maternal hypertension and its associated adverse effects.

(Choice C) Prenatal radiation exposure leads to cellular damage due to molecular bond disruption by free radicals. Fetuses exposed to radiation are at risk for cancer, particularly childhood leukemia.

(Choice E) Tobacco impairs oxygen delivery to fetal tissue and leads to multiple pregnancy complications, most notably intrauterine growth restriction and preterm delivery. Oligohydramnios and its fetal sequelae are not typically due to tobacco use.

(Choice F) Nonsteroidal anti-inflammatory drugs (NSAIDs) decrease the production of prostaglandin E1 and are avoided in the third trimester of pregnancy due to potential for premature closure of the ductus arteriosus. NSAIDs are not used to treat hypertension.

Educational objective:
Fetopathy due to angiotensin-converting enzyme inhibitors or angiotensin II receptor blockers results from blockade of angiotensin II, which is necessary for normal renal development. Use of these antihypertensive drugs during pregnancy can result in fetal anuria, oligohydramnios, pulmonary hypoplasia, limb contractures, and calvarium defects.

References

- Potter's sequence.
- Pregnancy outcome following exposure to angiotensin-converting enzyme inhibitors or angiotensin receptor antagonists: a systematic review.

angiotensin II levels can result in fetal renal maldevelopment, which in turn leads to reduced diuresis and **oligohydramnios**. Severe oligohydramnios can result in pulmonary hypoplasia and skeletal defects. In addition, low angiotensin II levels may result in impaired cranial vascularization and **hypocalvaria** (hypoplasia of skull bones).

(Choices A and B) Methyldopa, an alpha 2-adrenergic agonist, and labetalol, a beta-adrenergic antagonist, are first-line antihypertensive medications in pregnancy. Although labetalol can cause fetal/neonatal bradycardia, hypoglycemia, and hypotension, neither medication causes congenital malformations. Instead, fetal outcomes are improved by reducing maternal hypertension and its associated adverse effects.

(Choice C) Prenatal radiation exposure leads to cellular damage due to molecular bond disruption by free radicals. Fetuses exposed to radiation are at risk for cancer, particularly childhood leukemia.

(Choice E) Tobacco impairs oxygen delivery to fetal tissue and leads to multiple pregnancy complications, most notably intrauterine growth restriction and preterm delivery. Oligohydramnios and its fetal sequelae are not typically due to tobacco use.

(Choice F) Nonsteroidal anti-inflammatory drugs (NSAIDs) decrease the production of prostaglandin E1 and are avoided in the third trimester of pregnancy due to potential for premature closure of the ductus arteriosus. NSAIDs are not used to treat hypertension.

Educational objective:
Fetopathy due to angiotensin-converting enzyme inhibitors or angiotensin II receptor blockers results from blockade of angiotensin II, which is necessary for normal renal development. Use of these antihypertensive drugs during pregnancy can result in fetal anuria, oligohydramnios, pulmonary hypoplasia, limb contractures, and calvarium defects.

References

- Potter's sequence.
- Pregnancy outcome following exposure to angiotensin-converting enzyme inhibitors or angiotensin receptor antagonists: a systematic review.

Pharmacology	Pregnancy, Childbirth & Puerperium	ACE inhibitors
Subject	System	Topic

Copyright © UWorld. All rights reserved.

A 27-year-old nulligravid woman comes to the office for a routine visit. Her past medical history is significant for epilepsy that is well controlled with valproate and chronic hypertension for which she takes labetalol. She is hoping to conceive in the next few months and planning to start prenatal vitamins soon. The patient takes no other medications and does not use tobacco, alcohol, or illicit drugs. Blood pressure is 120/80 mm Hg. Physical examination findings are within normal limits. If the patient conceives now, which of the following is most likely to develop in her offspring?

A. Epiphyseal stippling
B. Hypothyroidism
C. Myelomeningocele
D. Nail hypoplasia
E. Renal dysgenesis
F. Short palpebral fissures
G. Tricuspid valve malformation

Submit

A 27-year-old nulligravid woman comes to the office for a routine visit. Her past medical history is significant for epilepsy that is well controlled with valproate and chronic hypertension for which she takes labetalol. She is hoping to conceive in the next few months and planning to start prenatal vitamins soon. The patient takes no other medications and does not use tobacco, alcohol, or illicit drugs. Blood pressure is 120/80 mm Hg. Physical examination findings are within normal limits. If the patient conceives now, which of the following is most likely to develop in her offspring?

- A. Epiphyseal stippling (1%)
- B. Hypothyroidism (2%)
- ✓ C. Myelomeningocele (70%)
- D. Nail hypoplasia (4%)
- E. Renal dysgenesis (10%)
- F. Short palpebral fissures (2%)
- G. Tricuspid valve malformation (7%)

Omitted
Correct answer
C

70%
Answered correctly

03 secs
Time Spent

03/19/2020
Last Updated

Explanation

Teratogenic medications	

Teratogenic medications	
Drug	**Adverse effects**
Phenytoin	Neural tube defects, orofacial clefts, microcephaly, nail or digit hypoplasia
Lithium	Ebstein anomaly, nephrogenic diabetes insipidus, hypothyroidism
Valproate	Neural tube defects
Isotretinoin	Microcephaly, thymic hypoplasia, small ears, hydrocephalus
Methotrexate	Limb & craniofacial abnormalities, neural tube defects, abortion
ACE inhibitors	Renal dysgenesis, oligohydramnios
Warfarin	Nasal hypoplasia, stippled epiphysis

Valproate is used to prevent migraines and treat epilepsy and bipolar disorder. Compared to other antiepileptics, valproate is associated with increased risk of teratogenicity and is **contraindicated** in pregnancy. Valproate interferes with folate metabolism and its use, particularly in the first trimester, significantly increases the risk of neural tube defects (eg, meningocele, myelomeningocele) compared to the general population. Because most women discover they are pregnant after the vulnerable period of neural tube formation (eg, 4th week of gestation), patients on valproate should try to optimize seizure control prior to conception with another anticonvulsant (eg, levetiracetam). Low-dose **folate** is recommended in all women **before conceiving**. High-dose folate is recommended in the presence of risk factors such as use of valproate or a prior child with neural tube defects.

(Choice A) First-trimester exposure to warfarin can lead to "warfarin embryopathy," which is characterized by depression of the nasal bridge and stippling (pinpoint calcification) of the epiphyses. Warfarin use during pregnancy can also cause nail hypoplasia and fetal bleeding. This patient is not on warfarin.

(Choices B and G) Hypothyroidism and Ebstein anomaly are complications associated with maternal lithium use during pregnancy. Neonatal hypothyroidism can also result from exposure to maternal antithyroid drugs (eg, propylthiouracil, methimazole)

Valproate is used to prevent migraines and treat epilepsy and bipolar disorder. Compared to other antiepileptics, valproate is associated with increased risk of teratogenicity and is **contraindicated** in pregnancy. Valproate interferes with folate metabolism and its use, particularly in the first trimester, significantly increases the risk of neural tube defects (eg, meningocele, myelomeningocele) compared to the general population. Because most women discover they are pregnant after the vulnerable period of neural tube formation (eg, 4th week of gestation), patients on valproate should try to optimize seizure control prior to conception with another anticonvulsant (eg, levetiracetam). Low-dose **folate** is recommended in all women **before conceiving**. High-dose folate is recommended in the presence of risk factors such as use of valproate or a prior child with neural tube defects.

(Choice A) First-trimester exposure to warfarin can lead to "warfarin embryopathy," which is characterized by depression of the nasal bridge and stippling (pinpoint calcification) of the epiphyses. Warfarin use during pregnancy can also cause nail hypoplasia and fetal bleeding. This patient is not on warfarin.

(Choices B and G) Hypothyroidism and Ebstein anomaly are complications associated with maternal lithium use during pregnancy. Neonatal hypothyroidism can also result from exposure to maternal antithyroid drugs (eg, propylthiouracil, methimazole).

(Choice D) Phenytoin is an antiepileptic that is teratogenic in the first trimester. Fetal hydantoin syndrome is characterized by orofacial clefts, microcephaly, nail or digit hypoplasia, cardiac defects, and dysmorphic facial features.

(Choice E) Renal dysgenesis and fetal anuria/oligohydramnios can result from use of angiotensin-converting enzyme inhibitors and angiotensin receptor blockers during pregnancy. These antihypertensive drugs are contraindicated in pregnancy.

(Choice F) Short palpebral fissures, smooth philtrum, and a thin vermillion border are the key dysmorphic features of fetal alcohol syndrome. This patient does not use alcohol.

Educational objective:
Valproate decreases levels of folic acid and increases the risk of neural tube defects (eg, meningocele, myelomeningocele).

References

- Treating epilepsy in pregnant women.
- Comparative safety of antiepileptic drugs during pregnancy.
- Valproic acid in pregnancy: how much are we endangering the embryo and fetus?

Valproate is used to prevent migraines and treat epilepsy and bipolar disorder. Compared to other antiepileptics, valproate is associated with

Exhibit Display

Spina bifida

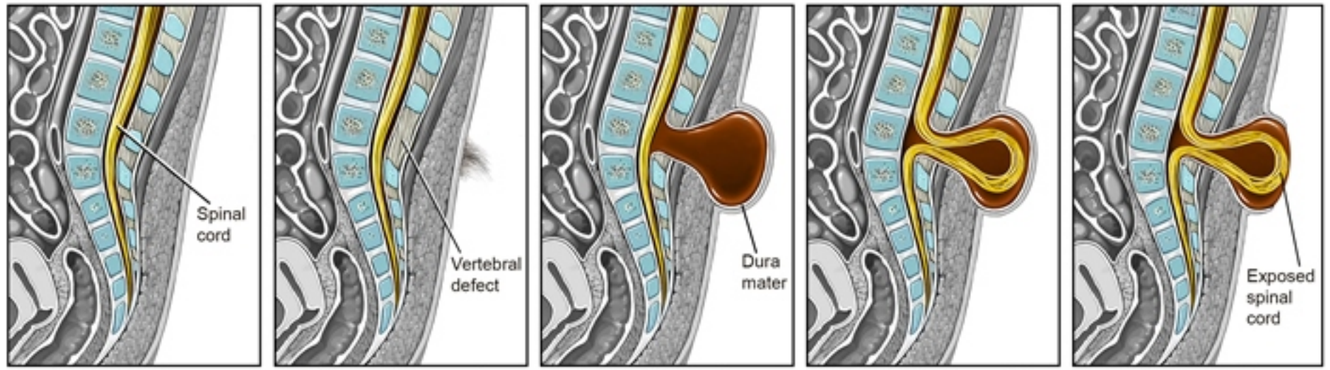

Normal spine | Spina bifida occulta | Meningocele | Myelomeningocele | Myeloschisis

©UWorld

Zoom In | Zoom Out | Reset | Add To New Card | Existing Card

- Valproic acid in pregnancy: how much are we endangering the embryo and fetus?

Valproate is used to prevent migraines and treat epilepsy and bipolar disorder. Compared to other antiepileptics, valproate is associated with

Exhibit Display

Zoom In | Zoom Out | Reset | Add To New Card | Existing Card

- Valproic acid in pregnancy: how much are we endangering the embryo and fetus?

first trimester, significantly increases the risk of neural tube defects (eg, meningocele, myelomeningocele) compared to the general population.

Exhibit Display

Fetal alcohol syndrome

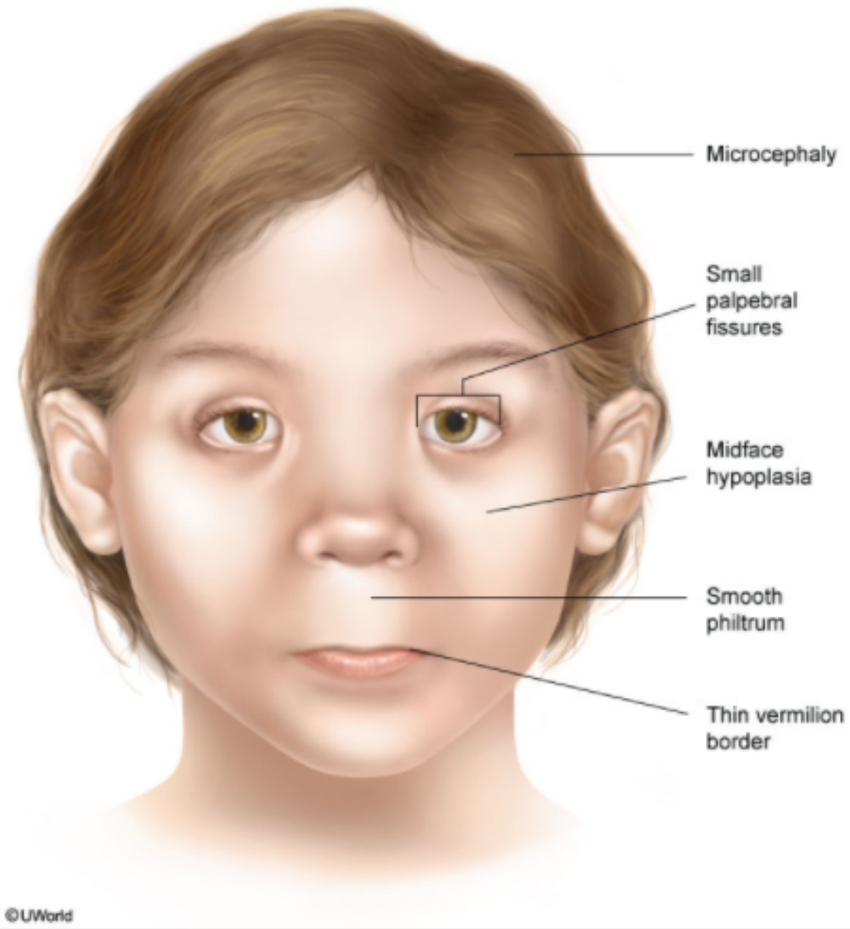

Zoom In | Zoom Out | Reset | Add To New Card | Existing Card

Pharmacology Pregnancy, Childbirth & Puerperium Teratogens

A 22-year-old man comes to the office due to erectile dysfunction and lack of sexual desire. Medical history is unremarkable. The patient is in a stable relationship with his fiancé and does not use tobacco, alcohol, or illicit drugs. Height is 188 cm (6 ft 2 in) and weight is 88 kg (194 lb). Examination shows bilateral gynecomastia, sparse facial hair, and small, firm testes. The penis is normal in size and peripheral vision is normal on confrontation. This patient would most benefit from which of the following?

A. Aromatase inhibitor

B. Gonadotropin

C. Phosphodiesterase 5 inhibitor

D. Selective estrogen receptor modulator

E. Testosterone

Submit

A 22-year-old man comes to the office due to erectile dysfunction and lack of sexual desire. Medical history is unremarkable. The patient is in a stable relationship with his fiancé and does not use tobacco, alcohol, or illicit drugs. Height is 188 cm (6 ft 2 in) and weight is 88 kg (194 lb). Examination shows bilateral gynecomastia, sparse facial hair, and small, firm testes. The penis is normal in size and peripheral vision is normal on confrontation. This patient would most benefit from which of the following?

A. Aromatase inhibitor (32%)
B. Gonadotropin (8%)
C. Phosphodiesterase 5 inhibitor (3%)
D. Selective estrogen receptor modulator (3%)
✓ E. Testosterone (52%)

Omitted
Correct answer
E

52%
Answered correctly

02 secs
Time Spent

05/07/2020
Last Updated

Explanation

Male primary hypogonadism	
Causes	• Congenital: chromosomal disorders (eg, Klinefelter syndrome), cryptorchidism • Acquired: cancer chemotherapy, hemochromatosis, aging
Clinical	• Symptoms: low libido, erectile dysfunction, loss of muscle mass, infertility • Signs: gynecomastia, decreased body hair, low bone density

Male primary hypogonadism	
Causes	• Congenital: chromosomal disorders (eg, Klinefelter syndrome), cryptorchidism • Acquired: cancer chemotherapy, hemochromatosis, aging
Clinical findings	• Symptoms: low libido, erectile dysfunction, loss of muscle mass, infertility • Signs: gynecomastia, decreased body hair, low bone density • Laboratory diagnosis: low serum testosterone, high LH & FSH
Treatment	• Transdermal or injected testosterone

This patient has features of testosterone deficiency (ie, **hypogonadism**), including erectile dysfunction, low libido, and gynecomastia. His **tall stature** and **small, firm testes** are consistent with Klinefelter syndrome (KS), which causes hypogonadism due to hyalinization and fibrosis of the testes. Patients who develop hypogonadism prior to puberty, including patients with KS, often have a eunuchoid habitus, sparse body hair, and high-pitched voice, whereas these features are much less pronounced in those who develop hypogonadism later in life.

Primary hypogonadism can be confirmed with **low serum testosterone** associated with **elevated LH**. Management of male hypogonadism includes **testosterone therapy**, which can improve libido and erectile function, increase bone density, and facilitate muscle development.

(Choice A) Aromatase inhibitors decrease the conversion of androgens to the corresponding estrogens (eg, testosterone to estradiol). Although some experts use aromatase inhibitors as supplemental therapy in KS, the primary defect is inadequate testosterone production, so testosterone therapy should be initiated first.

(Choice B) hCG has bioactivity analogous to that of LH and can be used to stimulate testosterone production in patients with secondary/central hypogonadism (ie, low endogenous LH). However, patients with KS have primary hypogonadism, so gonadotropin therapy is not useful.

(Choice C) Phosphodiesterase 5 inhibitors (eg, sildenafil) can assist in the treatment of erectile dysfunction but would not improve this patient's hormone levels or libido.

(Choice D) Selective estrogen receptor modulators (eg, tamoxifen) are sometimes used to minimize breast enlargement in adolescents with KS. However, nonsurgical interventions are not useful in adults with established gynecomastia.

stature and **small, firm testes** are consistent with Klinefelter syndrome (KS), which causes hypogonadism due to hyalinization and fibrosis of the testes. Patients who develop hypogonadism prior to puberty, including patients with KS, often have a eunuchoid habitus, sparse body hair, and high-pitched voice, whereas these features are much less pronounced in those who develop hypogonadism later in life.

Primary hypogonadism can be confirmed with **low serum testosterone** associated with **elevated LH**. Management of male hypogonadism includes **testosterone therapy**, which can improve libido and erectile function, increase bone density, and facilitate muscle development.

(Choice A) Aromatase inhibitors decrease the conversion of androgens to the corresponding estrogens (eg, testosterone to estradiol). Although some experts use aromatase inhibitors as supplemental therapy in KS, the primary defect is inadequate testosterone production, so testosterone therapy should be initiated first.

(Choice B) hCG has bioactivity analogous to that of LH and can be used to stimulate testosterone production in patients with secondary/central hypogonadism (ie, low endogenous LH). However, patients with KS have primary hypogonadism, so gonadotropin therapy is not useful.

(Choice C) Phosphodiesterase 5 inhibitors (eg, sildenafil) can assist in the treatment of erectile dysfunction but would not improve this patient's hormone levels or libido.

(Choice D) Selective estrogen receptor modulators (eg, tamoxifen) are sometimes used to minimize breast enlargement in adolescents with KS. However, nonsurgical interventions are not useful in adults with established gynecomastia.

Educational objective:
Management of male hypogonadism includes testosterone therapy, which can improve libido and erectile function, increase bone density, and facilitate muscle development.

References

- Klinefelter syndrome and medical treatment: hypogonadism and beyond.

Pharmacology	Male Reproductive System	Male sexual dysfunction
Subject	System	Topic

Copyright © UWorld. All rights reserved.

A 21-year-old Caucasian woman comes to the office with facial flushing, headache, nausea, vomiting, and abdominal cramps after drinking alcohol at a party. Approximately 1 week ago, the patient was seen by a health care provider who prescribed a new oral medication. However, the patient cannot recall the name or reason it was prescribed. The patient also takes oral contraceptives and is sexually active with her boyfriend. She smokes cigarettes and drinks alcohol "sometimes." The patient is intoxicated and unable to provide further information. This patient is most likely being treated for which of the following conditions?

A. Anxiety
B. *Candida* vaginitis
C. Deep venous thrombosis
D. Menstrual cramps
E. Seasonal allergies
F. Trichomonas vaginitis

Submit

A 21-year-old Caucasian woman comes to the office with facial flushing, headache, nausea, vomiting, and abdominal cramps after drinking alcohol at a party. Approximately 1 week ago, the patient was seen by a health care provider who prescribed a new oral medication. However, the patient cannot recall the name or reason it was prescribed. The patient also takes oral contraceptives and is sexually active with her boyfriend. She smokes cigarettes and drinks alcohol "sometimes." The patient is intoxicated and unable to provide further information. This patient is most likely being treated for which of the following conditions?

A. Anxiety (17%)
B. *Candida* vaginitis (9%)
C. Deep venous thrombosis (3%)
D. Menstrual cramps (4%)
E. Seasonal allergies (2%)
✓ F. Trichomonas vaginitis (62%)

Omitted
Correct answer
F

62%
Answered correctly

02 secs
Time Spent

06/02/2020
Last Updated

Explanation

Alcohol metabolism

Alcohol metabolism

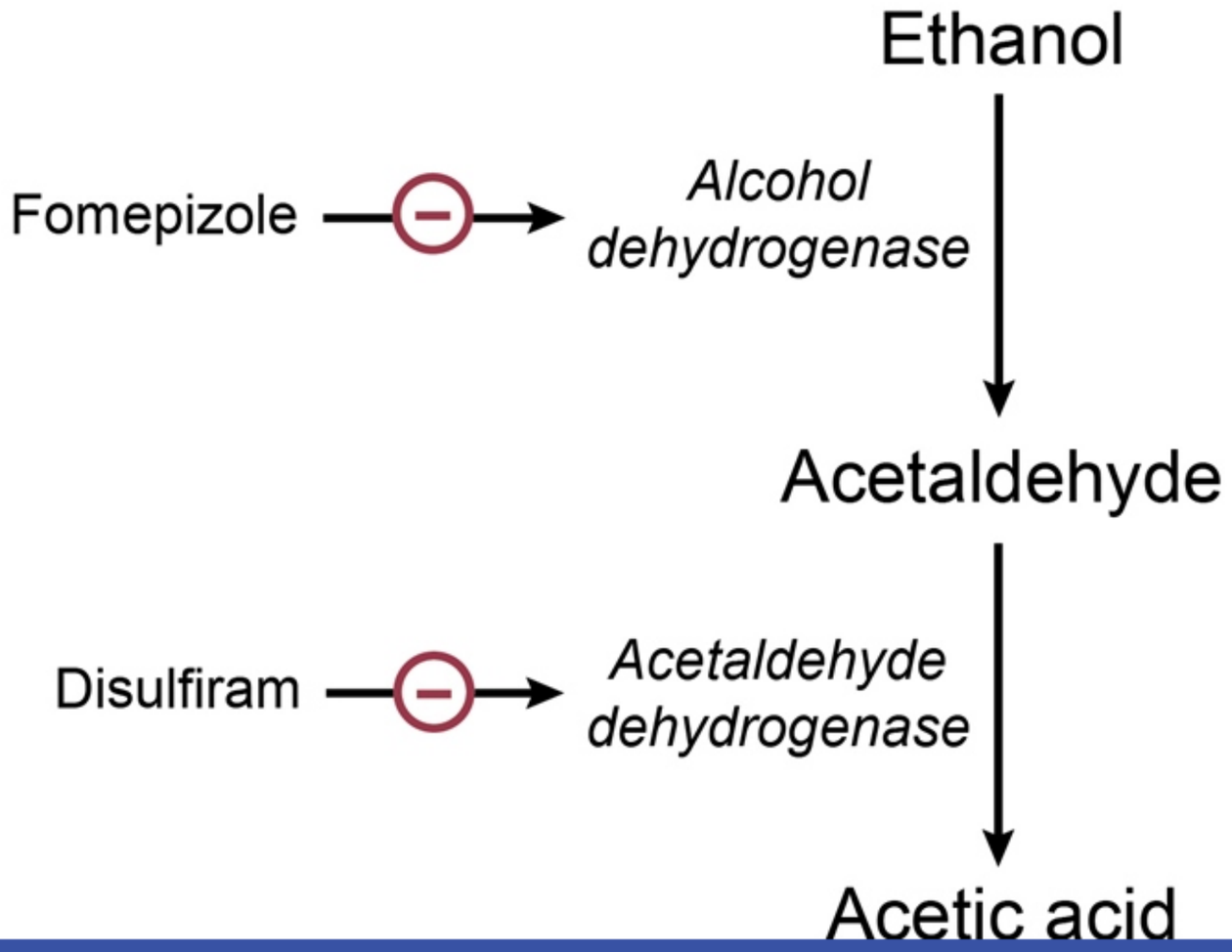

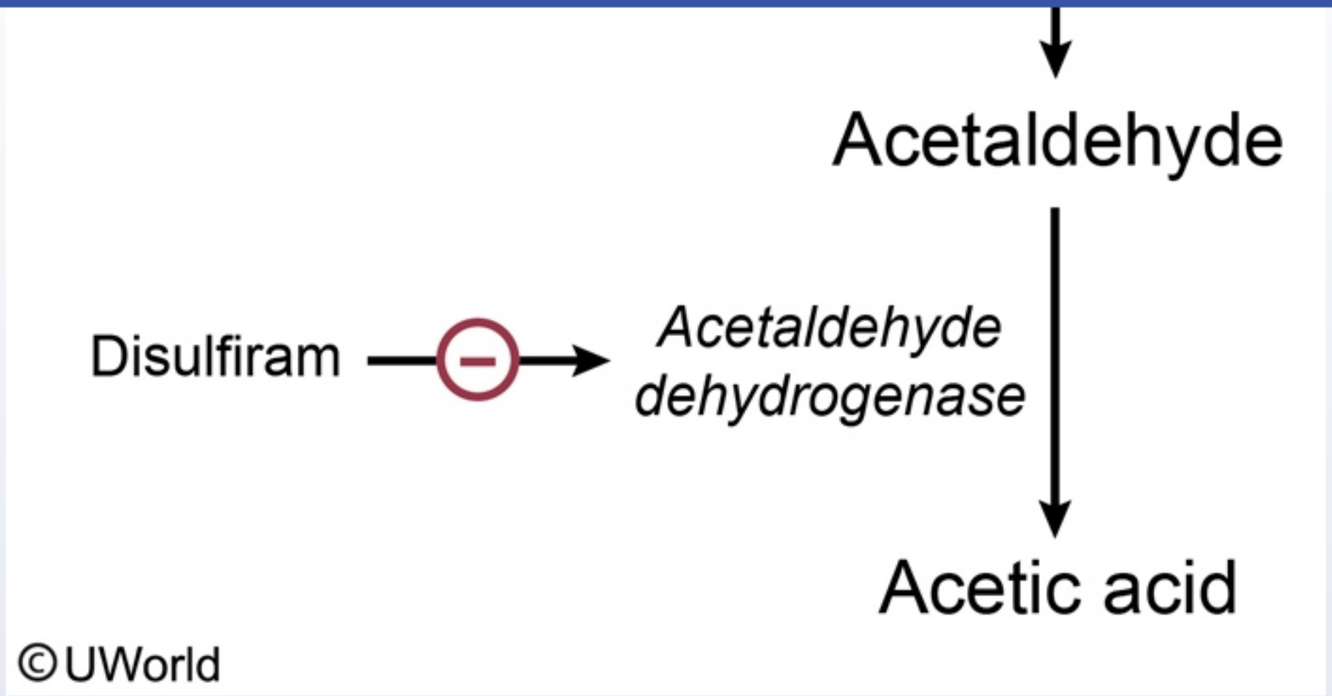

Medication-alcohol interactions can increase the risk of illness and injury. Patients receiving **metronidazole** can develop a **disulfiram-like reaction** shortly after **ethanol consumption**. Metronidazole is used to treat **trichomonas vaginitis** and **bacterial vaginosis**, and alcohol-containing beverages and medications should be avoided during the treatment course.

Although it is not well tolerated, disulfiram is a medication that can be used in recovering alcoholics to prevent relapse. This drug inhibits acetaldehyde dehydrogenase and causes **acetaldehyde accumulation**. Metronidazole's interaction with alcohol is similar to that with disulfiram, exhibiting comparable systemic adverse effects such as headache, abdominal cramps, nausea, and flushing.

(Choices A and E) Benzodiazepines are a treatment option for anxiety. Allergies can be treated with antihistamines. Alcohol use with both of these medication classes is dangerous as it intensifies sedative and depressive effects.

(Choice B) *Candida* vaginitis is treated with fluconazole, a fungistatic drug that inhibits ergosterol synthesis in the P450 system of fungi.

(Choice C) The combination of oral contraceptive use and smoking increases the risk of thrombosis, especially in women over age 35. Deep

Medication-alcohol interactions can increase the risk of illness and injury. Patients receiving **metronidazole** can develop a **disulfiram-like reaction** shortly after **ethanol consumption**. Metronidazole is used to treat **trichomonas vaginitis** and **bacterial vaginosis**, and alcohol-containing beverages and medications should be avoided during the treatment course.

Although it is not well tolerated, disulfiram is a medication that can be used in recovering alcoholics to prevent relapse. This drug inhibits acetaldehyde dehydrogenase and causes **acetaldehyde accumulation**. Metronidazole's interaction with alcohol is similar to that with disulfiram, exhibiting comparable systemic adverse effects such as headache, abdominal cramps, nausea, and flushing.

(Choices A and E) Benzodiazepines are a treatment option for anxiety. Allergies can be treated with antihistamines. Alcohol use with both of these medication classes is dangerous as it intensifies sedative and depressive effects.

(Choice B) *Candida* vaginitis is treated with fluconazole, a fungistatic drug that inhibits ergosterol synthesis in the P450 system of fungi.

(Choice C) The combination of oral contraceptive use and smoking increases the risk of thrombosis, especially in women over age 35. Deep venous thrombosis is treated with anticoagulants (eg, warfarin), and alcohol consumption can alter warfarin's bioavailability and a patient's bleeding or clotting risk.

(Choice D) Menstrual cramps are treated with nonsteroidal anti-inflammatory drugs (NSAIDs) or oral contraceptives. NSAIDs inhibit cyclooxygenase and cause gastric bleeding which can be exacerbated by alcohol but do not cause a systemic reaction.

Educational objective:
Metronidazole is used to treat trichomonal vaginitis and bacterial vaginosis. It can cause disulfiram-like effects (eg, abdominal cramps, nausea, headache) when combined with alcohol due to acetaldehyde accumulation.

References

- Vulvovaginitis: screening for and management of trichomoniasis, vulvovaginal candidiasis, and bacterial vaginosis.

Pharmacology	Female Reproductive System & Breast	Nitroimidazole antibiotics
Subject	System	Topic

Copyright © UWorld. All rights reserved.

A 33-year-old woman, gravida 2 para 1, comes to the office due to a positive home urine pregnancy test. Her last menstrual period was 6 weeks ago, and pelvic ultrasonography confirms an intrauterine pregnancy. The patient has idiopathic pulmonary hypertension complicated by Eisenmenger syndrome. She is aware that pregnancy poses a major mortality risk to herself and the fetus due to the hemodynamic changes of gestation, labor, and delivery. The patient consents to pregnancy termination with a mifepristone and misoprostol regimen. Which of the following is the mechanism of action for mifepristone in this clinical situation?

- A. Calcium channel blocker
- B. Cyclooxygenase inhibitor
- C. Folic acid antagonist
- D. Oxytocin receptor agonist
- E. Progesterone antagonist
- F. Prostaglandin agonist
- G. Selective estrogen receptor modulator

Submit

A 33-year-old woman, gravida 2 para 1, comes to the office due to a positive home urine pregnancy test. Her last menstrual period was 6 weeks ago, and pelvic ultrasonography confirms an intrauterine pregnancy. The patient has idiopathic pulmonary hypertension complicated by Eisenmenger syndrome. She is aware that pregnancy poses a major mortality risk to herself and the fetus due to the hemodynamic changes of gestation, labor, and delivery. The patient consents to pregnancy termination with a mifepristone and misoprostol regimen. Which of the following is the mechanism of action for mifepristone in this clinical situation?

- A. Calcium channel blocker (0%)
- B. Cyclooxygenase inhibitor (1%)
- C. Folic acid antagonist (3%)
- D. Oxytocin receptor agonist (10%)
- ✓ E. Progesterone antagonist (67%)
- F. Prostaglandin agonist (16%)
- G. Selective estrogen receptor modulator (1%)

Omitted
Correct answer
E

67%
Answered correctly

02 secs
Time Spent

02/20/2020
Last Updated

Explanation

Medications used for pregnancy termination

Medications used for pregnancy termination

Medication	Mechanism of action
Misoprostol	• Prostaglandin E1 agonist
Mifepristone	• Progesterone antagonist • Glucocorticoid antagonist
Methotrexate	• Folic acid antagonist

©UWorld

In the second half of the menstrual cycle, progesterone stimulates the development of secretory endometrium to create an environment favorable for implantation. In the first 7 weeks of pregnancy, progesterone is secreted by the corpus luteum; thereafter, its production is assumed by the placenta. **Mifepristone** is a **progesterone antagonist** that binds progesterone receptors with greater affinity than the natural hormone. Progesterone receptor blockade results in apoptosis and **necrosis of the uterine decidua** and prevents further development of a first trimester pregnancy.

When misoprostol is used with mifepristone, pregnancy termination success rate is increased. **Misoprostol**, a **prostaglandin E1 analog (Choice F)**, causes cervical softening and uterine contractions leading to expulsion of the pregnancy.

(Choices A and B) Nifedipine (calcium channel blocker) and indomethacin (cyclooxygenase inhibitor) are tocolytic drugs used to stop preterm labor. The decreased intracellular calcium from nifedipine blocks myosin kinase phosphorylation, which in turn leads to myometrial relaxation. Indomethacin stops prostaglandin synthesis, which decreases uterine contractility.

(Choice C) Folic acid antagonists (eg, methotrexate) inhibit trophoblast division, therefore decreasing trophoblast survival, hindering implantation, and encouraging expulsion. Methotrexate is used for the treatment of ectopic pregnancy and for termination of intrauterine pregnancy in conjunction with misoprostol when mifepristone is not available.

In the second half of the menstrual cycle, progesterone stimulates the development of secretory endometrium to create an environment favorable for implantation. In the first 7 weeks of pregnancy, progesterone is secreted by the corpus luteum; thereafter, its production is assumed by the placenta. **Mifepristone** is a **progesterone antagonist** that binds progesterone receptors with greater affinity than the natural hormone. Progesterone receptor blockade results in apoptosis and **necrosis of the uterine decidua** and prevents further development of a first trimester pregnancy.

When misoprostol is used with mifepristone, pregnancy termination success rate is increased. **Misoprostol**, a **prostaglandin E1 analog (Choice F)**, causes cervical softening and uterine contractions leading to expulsion of the pregnancy.

(Choices A and B) Nifedipine (calcium channel blocker) and indomethacin (cyclooxygenase inhibitor) are tocolytic drugs used to stop preterm labor. The decreased intracellular calcium from nifedipine blocks myosin kinase phosphorylation, which in turn leads to myometrial relaxation. Indomethacin stops prostaglandin synthesis, which decreases uterine contractility.

(Choice C) Folic acid antagonists (eg, methotrexate) inhibit trophoblast division, therefore decreasing trophoblast survival, hindering implantation, and encouraging expulsion. Methotrexate is used for the treatment of ectopic pregnancy and for termination of intrauterine pregnancy in conjunction with misoprostol when mifepristone is not available.

(Choice D) Oxytocin is a peptide hormone released by the posterior pituitary that stimulates uterine contractions. Myometrial oxytocin receptor concentration increases at term; therefore, oxytocin has limited effects on the uterus in early gestation and does not cause pregnancy termination.

(Choice G) Tamoxifen is a selective estrogen receptor modulator and is used primarily to treat estrogen receptor-positive breast cancer by selective blockade of estrogen-positive cancer cells. Conversely, in the uterus, tamoxifen stimulates endometrial estrogen receptors and can cause endometrial hyperplasia and endometrial adenocarcinoma.

Educational objective:
Progesterone is necessary for implantation and maintenance of pregnancy. Mifepristone is a progesterone antagonist that is used with misoprostol (a prostaglandin-E1 agonist) to terminate a first-trimester pregnancy.

References

- Practice bulletin no. 143: medical management of first-trimester abortion.
- Biological mechanisms underlying the clinical effects of mifepristone (RU 486) on the endometrium.

A 24-year-old woman, gravida 1 para 1, comes to the office for an annual visit. The patient is up to date with cervical cancer screening and has completed the human papillomavirus vaccination series. She is in a monogamous relationship with her husband and has negative chlamydia and gonorrhea screening. The patient has been using a progestin-only pill since giving birth a year ago. She would like to switch to a combined oral contraceptive as she is no longer breastfeeding. Which of the following will be the primary mechanism of pregnancy prevention when the patient switches to a combined hormonal oral contraceptive?

A. Impairment of embryo implantation

B. Impairment of sperm penetration into the uterus

C. Increase in gonadotropin-releasing hormone activity

D. Intrauterine environment toxic to sperm

E. Reduction of serum gonadotropin levels

F. Reduction of serum prolactin level

Submit

A 24-year-old woman, gravida 1 para 1, comes to the office for an annual visit. The patient is up to date with cervical cancer screening and has completed the human papillomavirus vaccination series. She is in a monogamous relationship with her husband and has negative chlamydia and gonorrhea screening. The patient has been using a progestin-only pill since giving birth a year ago. She would like to switch to a combined oral contraceptive as she is no longer breastfeeding. Which of the following will be the primary mechanism of pregnancy prevention when the patient switches to a combined hormonal oral contraceptive?

A. Impairment of embryo implantation (12%)

B. Impairment of sperm penetration into the uterus (6%)

C. Increase in gonadotropin-releasing hormone activity (5%)

D. Intrauterine environment toxic to sperm (1%)

✓ E. Reduction of serum gonadotropin levels (73%)

F. Reduction of serum prolactin level (0%)

Omitted
Correct answer
E

73%
Answered correctly

02 secs
Time Spent

03/09/2020
Last Updated

Explanation

Contraceptives	
Methods	Primary mechanism of action

Contraceptives	
Methods	**Primary mechanism of action**
Systemic progestins • Combined hormonal contraceptive (pill, transdermal patch, vaginal ring) • Progestin implant/injection	Suppresses GnRH & pituitary gonadotropin secretion, inhibiting ovulation
Locally-acting progestins • Progestin-only (norethindrone) pill • Levonorgestrel IUD	Thickens cervical mucus, impairing sperm penetration
• Copper IUD	Creates chronic cytotoxic inflammatory response in uterus, impairing sperm migration

Combined = the combination of ethinyl estradiol & a progestin;
GnRH = gonadotropin-releasing hormone; **IUD** = intrauterine device.

©UWorld

Progestin, the synthetic equivalent to progesterone, is responsible for pregnancy prevention in all hormonal contraceptives. Estrogen is often included to improve the bleeding profile.

Progestin, the synthetic equivalent to progesterone, is responsible for pregnancy prevention in all hormonal contraceptives. Estrogen is often included to improve the bleeding profile.

The primary mechanism of action of a progestin depends on its pharmacokinetics (type of progestin, mode of administration, dose). Progestins that are more potent produce both **systemic** and local effects (levonorgestrel in pill form), whereas less potent progestins produce **local** uterine effects only (levonorgestrel released by the intrauterine device). **Combined hormonal contraceptives** exhibit systemic effects by **suppressing GnRH in the hypothalamus**, which decreases synthesis of the gonadotropins FSH and LH in the anterior pituitary. Because an LH spike is required to stimulate ovulation, **ovulation is inhibited**.

(Choice A) All progestin-containing contraceptives thin the uterine lining, which may theoretically impair embryo implantation. However, combined hormonal contraceptives prevent ovulation from occurring, thereby preventing the opportunity for fertilization in the first place and making this mechanism in pregnancy prevention unlikely.

(Choice B) The progestin-only pill (due to low dosage/potency) and levonorgestrel intrauterine device (IUD) prevent pregnancy by thickening cervical mucus, which prevents sperm from accessing the uterus. It lacks the systemic effects of combined hormonal contraceptives, and women continue to have ovulatory cycles.

(Choice C) The fertility drug clomiphene citrate is a selective estrogen receptor modulator that stimulates FSH and LH production, which in turn stimulates follicular development in the ovaries. Clomiphene citrate has the opposite effect of systemically acting progestins and increases the chance of pregnancy.

(Choice D) The copper IUD releases copper ions that elicit an inflammatory reaction in the uterus that is toxic to sperm and prevents fertilization.

(Choice F) Dopamine agonists (eg, bromocriptine, cabergoline) are used to treat hyperprolactinemia by decreasing prolactin secretion by binding dopamine receptors. Contraceptives do not have a direct effect on prolactin.

Educational objective:
All hormone-containing contraceptives prevent pregnancy through the actions of progestins. The main mechanism of contraceptives with systemically active progestins (eg, combined hormonal oral contraceptives) is inhibiting ovulation by decreasing FSH and LH synthesis in the anterior pituitary.

References

©UWorld

Exhibit Display

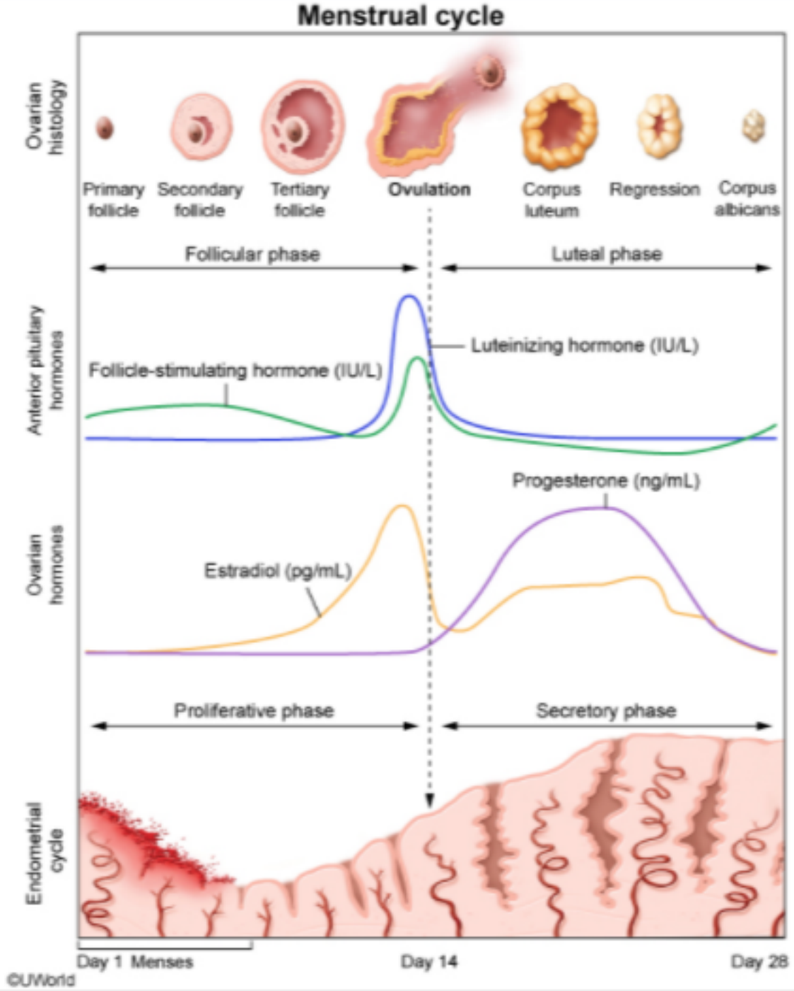

Zoom In | Zoom Out | Reset | Add To New Card | Existing Card

References

©UWorld

Exhibit Display

Levonorgestrel IUD

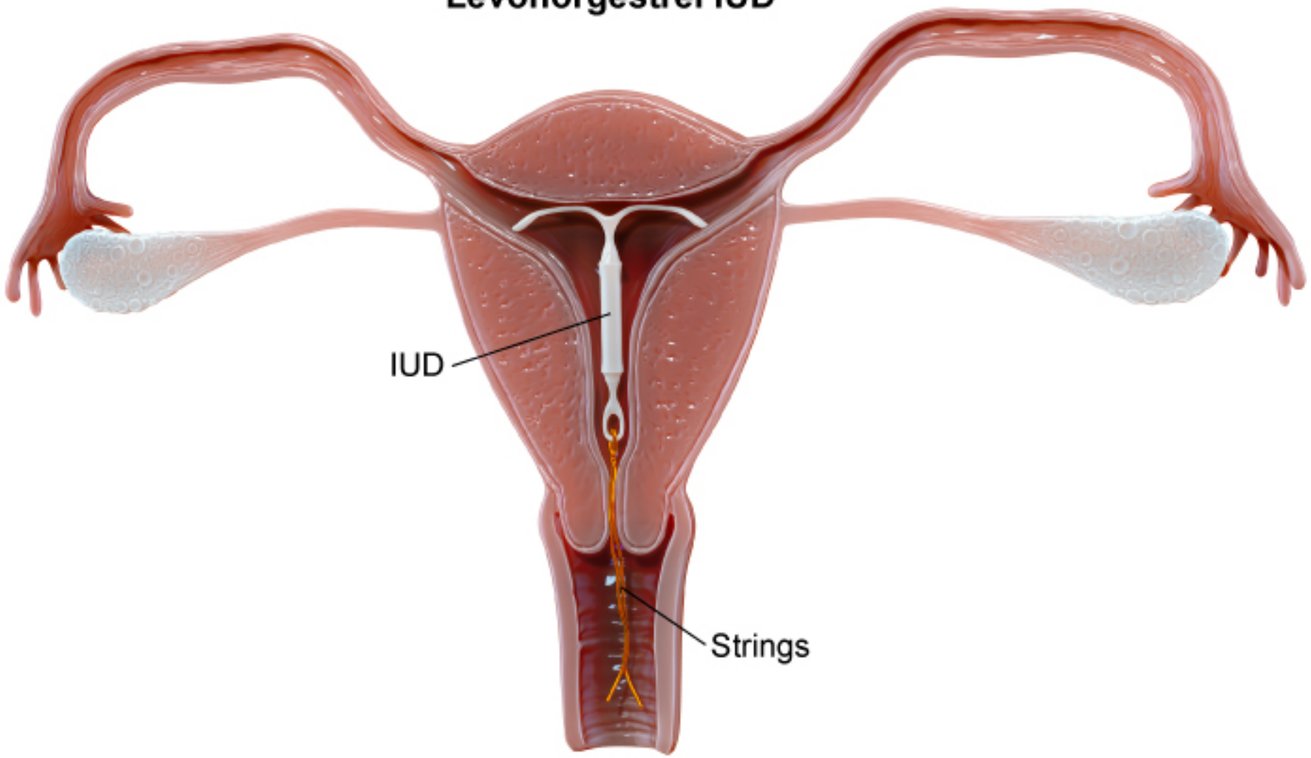

Thickens cervical mucus (blocks sperm entry)
Thins uterine lining (decreases menstrual bleeding)

IUD = intrauterine device.

©UWorld

Zoom In | Zoom Out | Reset | Add To New Card | Existing Card

References

©UWorld

Exhibit Display

Copper IUD

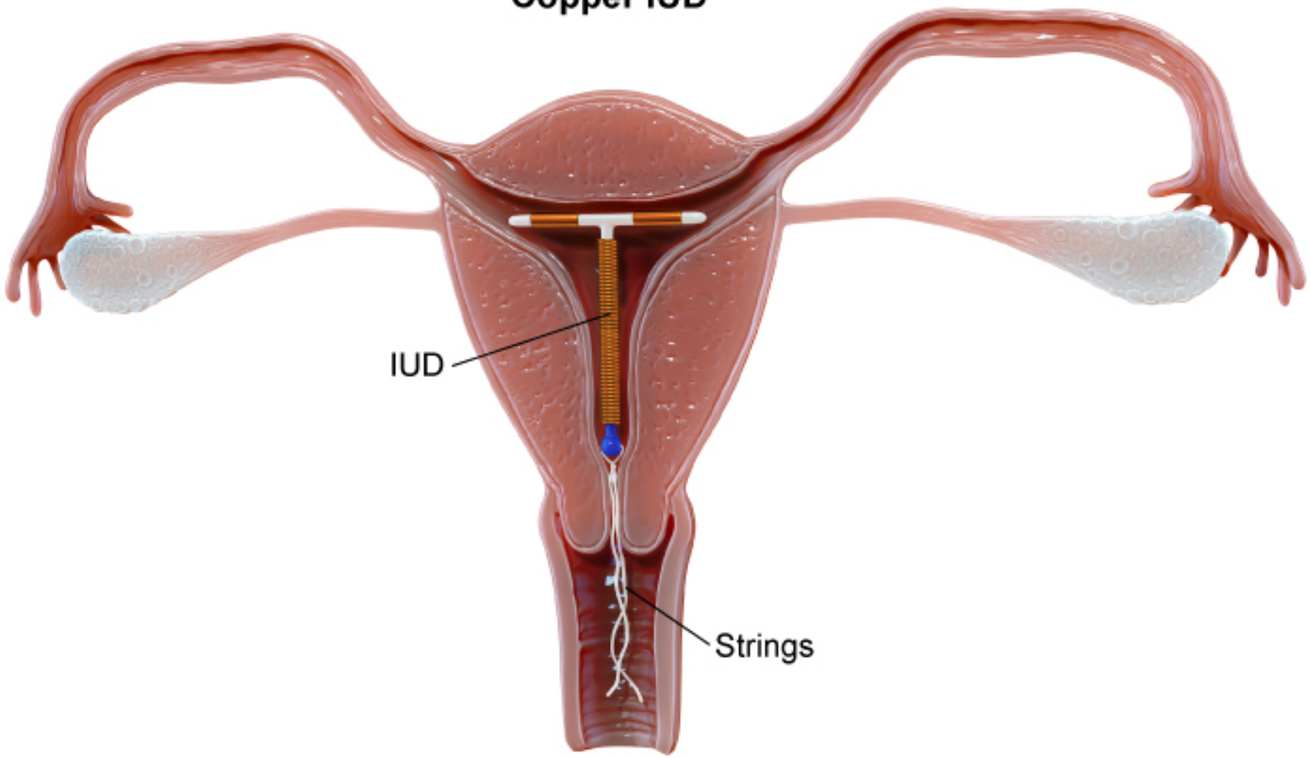

Causes endometrial inflammation
(toxic to sperm & ova)

IUD = intrauterine device.

©UWorld

Zoom In | Zoom Out | Reset | Add To New Card | Existing Card

References

A 7-year-old boy is evaluated for fatigue. For the last year, he has been avoiding any significant outdoor activities with his peers due to poor energy and shortness of breath. He also describes occasional pounding in the chest. Physical examination shows a holosystolic murmur best heard at the lower sternal border. Echocardiography reveals apical displacement of the tricuspid valve leaflets, decreased right ventricular volume, and atrialization of the right ventricle. Moderate to severe tricuspid regurgitation is also present. If this patient's diagnosis is due to a side effect of a drug taken during pregnancy, his biological mother most likely had which of the following conditions?

A. Alcohol abuse
B. Bipolar disorder
C. Cocaine abuse
D. Down syndrome
E. Epilepsy
F. Gestational diabetes
G. Hypothyroidism
H. Opioid abuse
I. Schizophrenia

Submit

A 7-year-old boy is evaluated for fatigue. For the last year, he has been avoiding any significant outdoor activities with his peers due to poor energy and shortness of breath. He also describes occasional pounding in the chest. Physical examination shows a holosystolic murmur best heard at the lower sternal border. Echocardiography reveals apical displacement of the tricuspid valve leaflets, decreased right ventricular volume, and atrialization of the right ventricle. Moderate to severe tricuspid regurgitation is also present. If this patient's diagnosis is due to a side effect of a drug taken during pregnancy, his biological mother most likely had which of the following conditions?

- A. Alcohol abuse (4%)
- ✓ B. Bipolar disorder (74%)
- C. Cocaine abuse (3%)
- D. Down syndrome (0%)
- E. Epilepsy (9%)
- F. Gestational diabetes (2%)
- G. Hypothyroidism (1%)
- H. Opioid abuse (0%)
- I. Schizophrenia (2%)

Omitted
Correct answer
B

74%
Answered correctly

02 secs
Time Spent

03/08/2020
Last Updated

Explanation

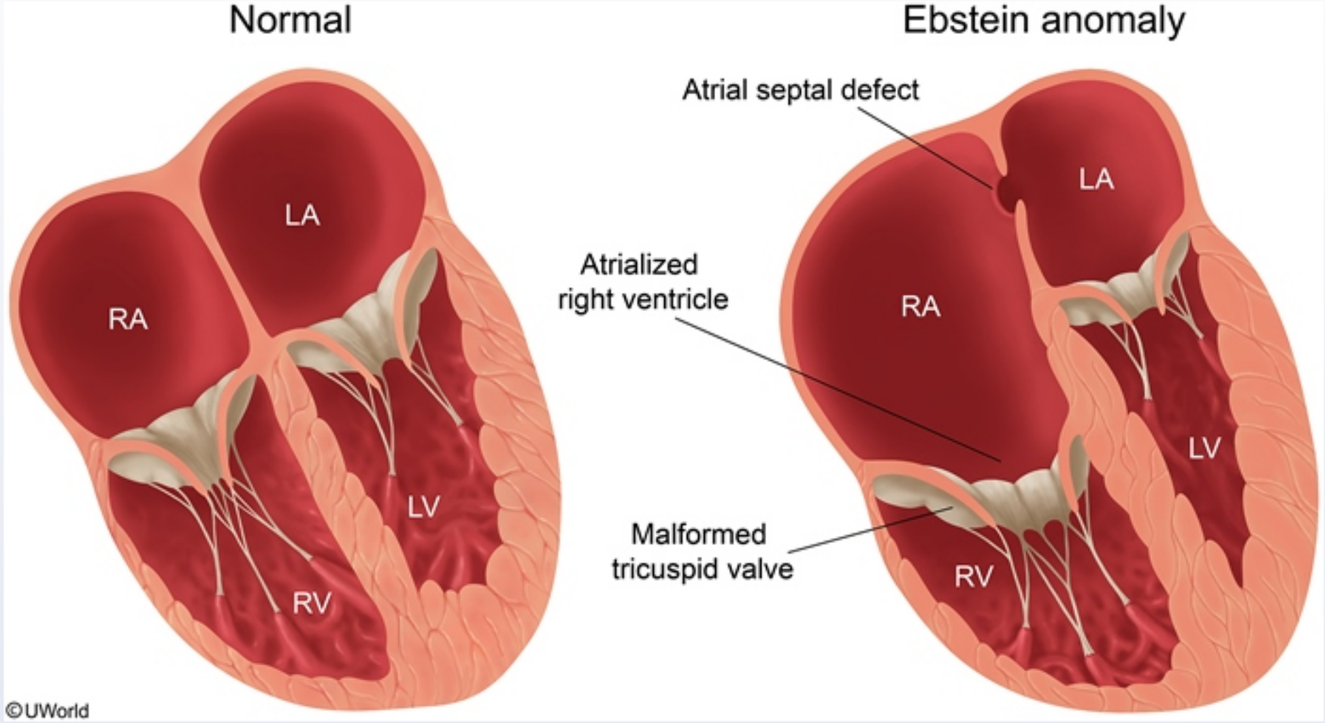

In patients with **bipolar disorder, lithium** is used to treat acute mania, hypomania, and bipolar and unipolar depression. Long-term treatment may also reduce the risk of suicide attempts and deaths. Lithium is potentially teratogenic; in utero exposure is associated with Ebstein's anomaly in infants. Ebstein's anomaly is characterized by apical displacement of the tricuspid valve leaflets, decreased volume of the right ventricle, and atrialization of the right ventricle.

(Choice A) Alcohol abuse during pregnancy may result in fetal alcohol syndrome, which is characterized by dysmorphic facies, growth retardation, and central nervous system abnormalities.

(Choice C) Prenatal cocaine abuse increases the risk of preeclampsia, spontaneous abortion, fetal demise, and placental abruption.

(Choice D) Atrial and ventricular septal defects are the most common congenital cardiac anomalies in patients with Down syndrome.

atrialization of the right ventricle.

(Choice A) Alcohol abuse during pregnancy may result in fetal alcohol syndrome, which is characterized by dysmorphic facies, growth retardation, and central nervous system abnormalities.

(Choice C) Prenatal cocaine abuse increases the risk of preeclampsia, spontaneous abortion, fetal demise, and placental abruption.

(Choice D) Atrial and ventricular septal defects are the most common congenital cardiac anomalies in patients with Down syndrome.

(Choice E) Seizures are not associated with major fetal malformations, but antiepileptic drugs (AEDs) significantly increase the risk of neural tube, renal, skeletal, and cleft palate abnormalities. Although AEDs also increase the risk of congenital heart defects, they are not associated with Ebstein's anomaly.

(Choice F) Gestational diabetes is associated with fetal macrosomia, caudal regression syndrome, hypoglycemia, hypocalcemia, and hypertrophic cardiomyopathy.

(Choice G) Untreated maternal hypothyroidism in pregnancy is associated with obstetric complications and cognitive impairment in offspring.

(Choice H) Opioid abuse may cause neonatal withdrawal symptoms (irritability, diarrhea, vomiting) after delivery. Opioid dependence increases the risk of multiple obstetric complications but not major cardiac defects.

(Choice I) Schizophrenia and antipsychotics are not associated with the development of major fetal malformations.

Educational objective:
Lithium is commonly used to treat bipolar disorder. Its use during pregnancy is associated with Ebstein's anomaly, which is characterized by apical displacement of the tricuspid valve leaflets, decreased right ventricular volume, and atrialization of the right ventricle.

References

- When lithium hurts: a look at Ebstein anomaly.
- Pregnancy outcome following in utero exposure to lithium: a prospective, comparative, observational study.
- Use and safety of antipsychotic drugs during pregnancy.